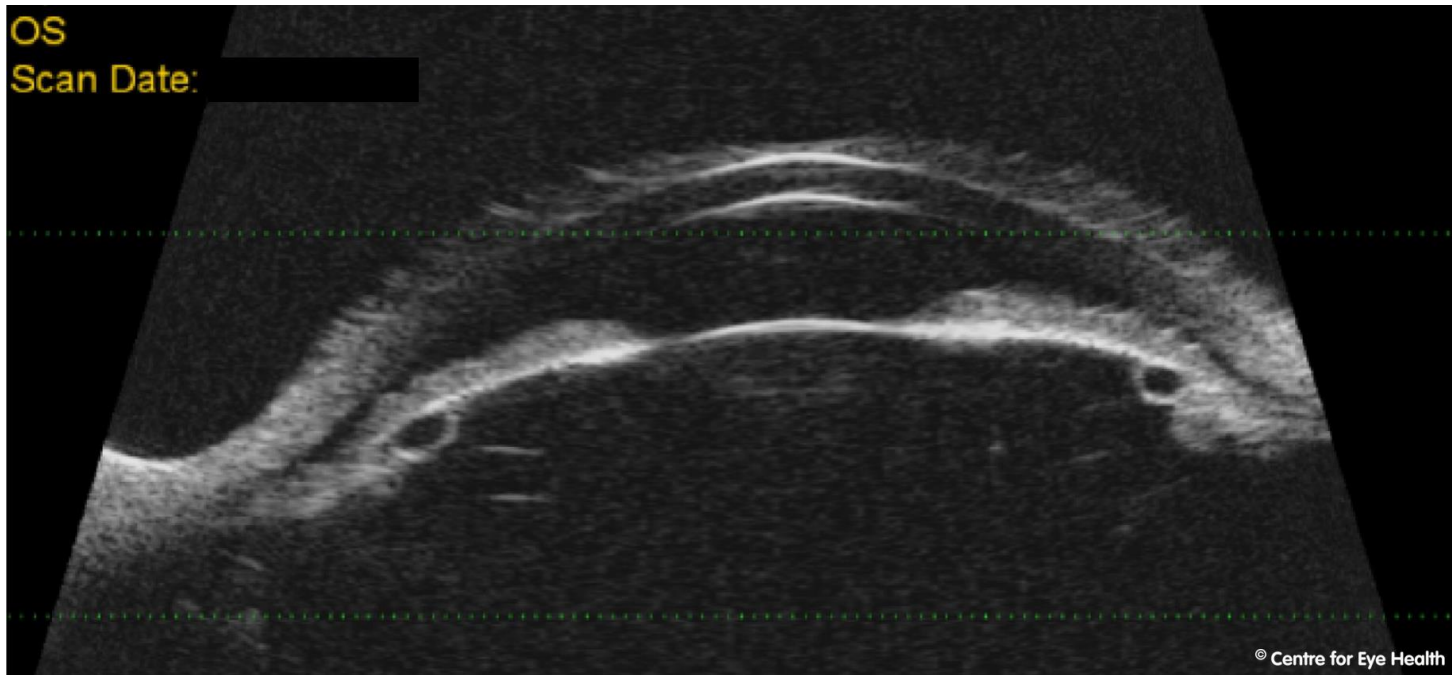




CFEH Facebook Case #155

A 60 year old Caucasian male was referred to the Centre for further investigation of his narrow angles. Ultrasound biomicroscopy (UBM) was used to produce the image shown below. Can you identify what has caused the narrow angles?



Answer

This patient has iridociliary cysts which are causing the iris to be pushed anteriorly, narrowing the angle.