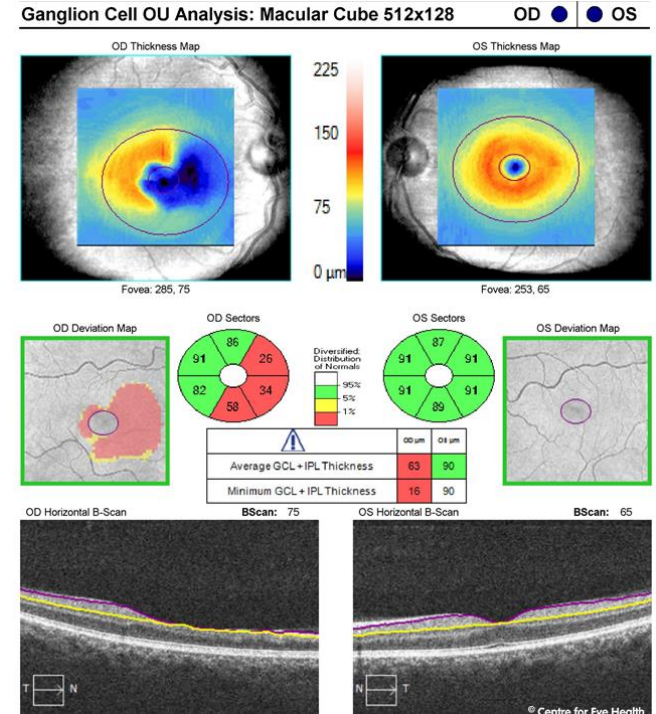
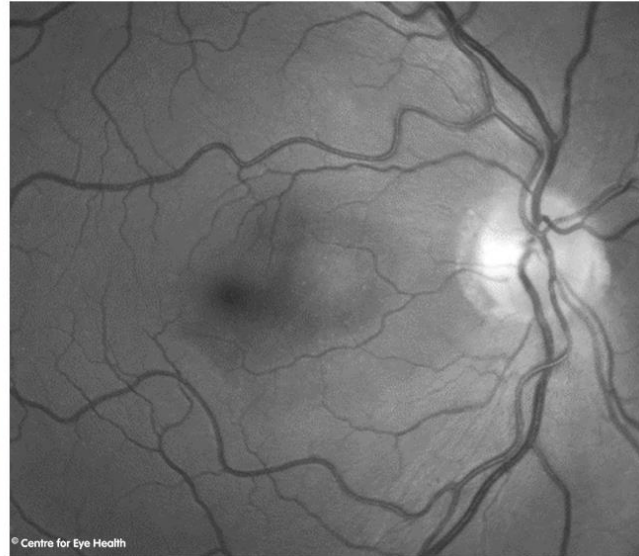
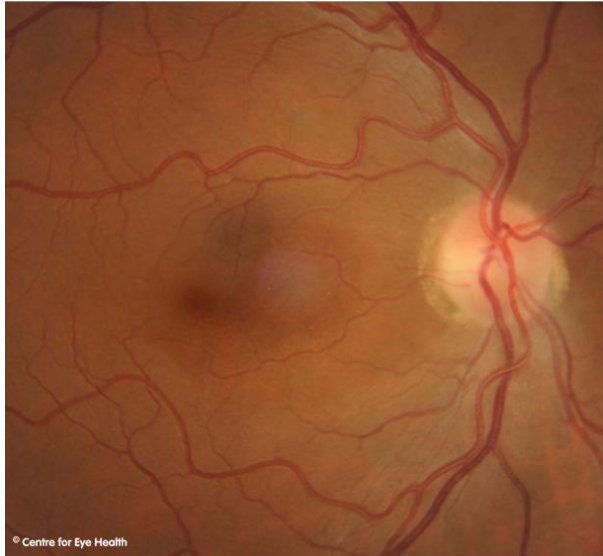
CFEH Facebook Case #88

A 50 year old European male reports a cloudiness in the vision of his right eye that he has noted since he was 15 years of age. He has recently started taking cholesterol medication and reports no other health concerns. What is the cause of the cloudiness in his vision?



Proudly brought to you by

LEARNING & VISION

Proudly brought to you by

LEARNING FOR VISION



Centre for Eye Health



Optometry

NEW SOUTH WALES
AUSTRALIAN CAPITAL TERRITORY

ANSWER

There is temporal disc pallor in the right eye with an associated wedge defect encompassing the papillomacular bundle and an absent macular reflex in this eye. The GCA also show marked loss of the inner retinal layers in this region. These clinical findings are consistent with an old occlusion of the cilioretinal artery. Additional findings include drupelets at the right macula and generalised vascular tortuosity with copper wiring and arteriovenous nipping. This patient was referred to an Ophthalmologist for further assessment.