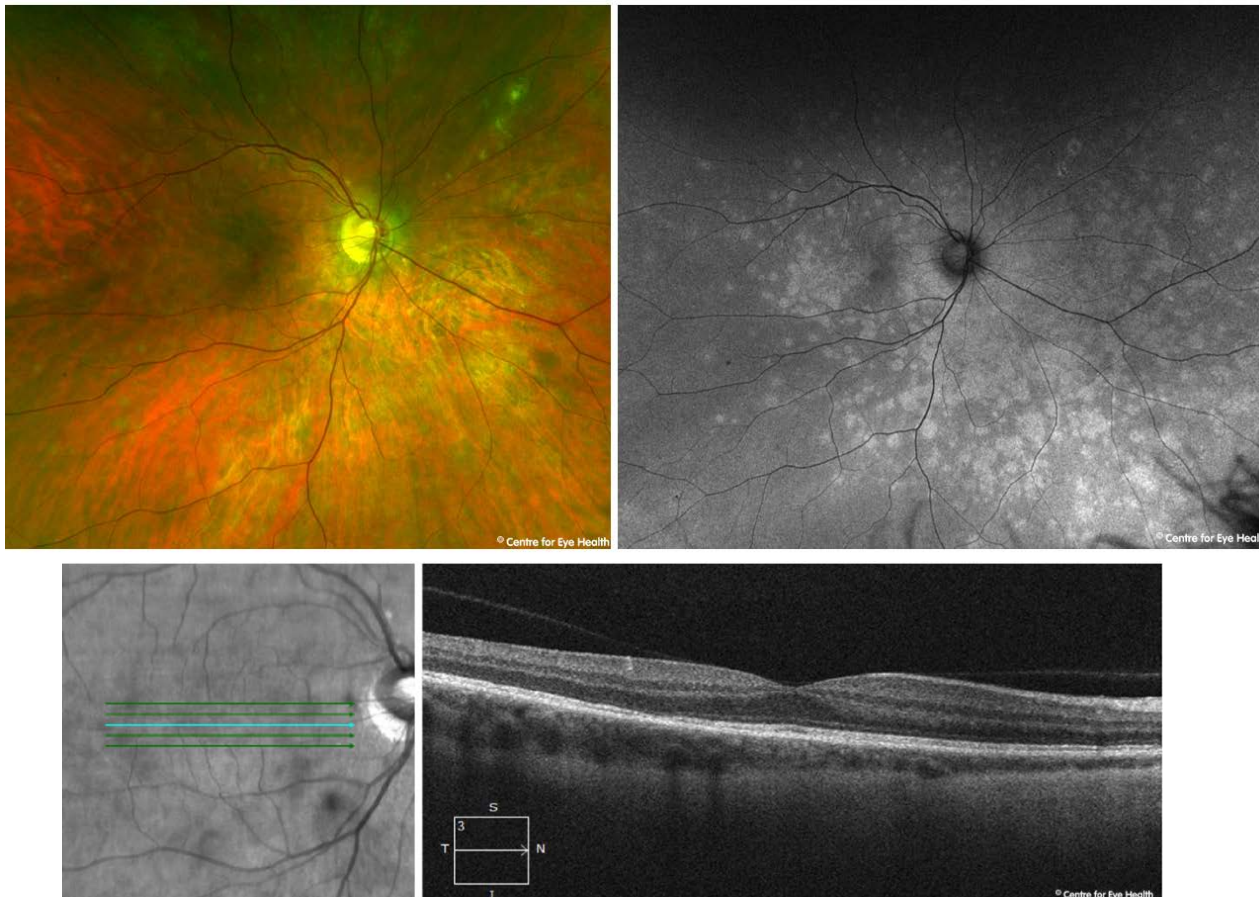




## CFEH Facebook Case #85

A 35 year old female presents complaining of photopsia and intermittent blur in her right eye for the last 1-2 weeks. Her visual acuity is 6/7.5 OU. Her fundus autofluorescence (FAF) and OCT Images are below. The left eye was unremarkable and thus not included here. What retinal condition would you suspect in this patient?



Proudly brought to you by

**LEARNING FOR VISION**



Centre for Eye Health



Optometry

NEW SOUTH WALES

AUSTRALIAN CAPITAL TERRITORY

# ANSWER

## Multiple Evanescent White Dot Syndrome

The fundus autofluorescence image shows multiple hyperfluorescent lesions at the posterior pole, particularly around the paramacular region, and extending to the nasal periphery. An OCT line scan through the macula shows small multiple outer retinal disruptions at the ellipsoid level and foveal granularity.

This presentation is consistent with a diagnosis of MEWDS. This is one of a group of retinal conditions termed “white dot syndromes” and is an idiopathic, spontaneously resolving inflammatory disorder typically affecting the 20 to 45 year age group with a strong female predilection. Symptoms can include a sudden reduction in visual acuity, photopsia, temporal or paracentral scotomas, and dyschromatopsia. The condition is usually unilateral, as in this case, however bilateral cases have been reported.

MEWDS has a good prognosis with recovery of the Ise line typically occurring over 4.5-6 weeks with concurrent resolution of the hyperautofluorescence. Rarely, some patients may have a persistent blind spot enlargement, photopsias, and dyschromatopsia.

For further information about this and other white dot syndromes, please refer to the CFEH paper “OCT and Fundus Autofluorescence Enhances Visualization of White Dot Syndromes” which can be downloaded using the following link:

<https://www.ncbi.nlm.nih.gov/pubmed/25875689>