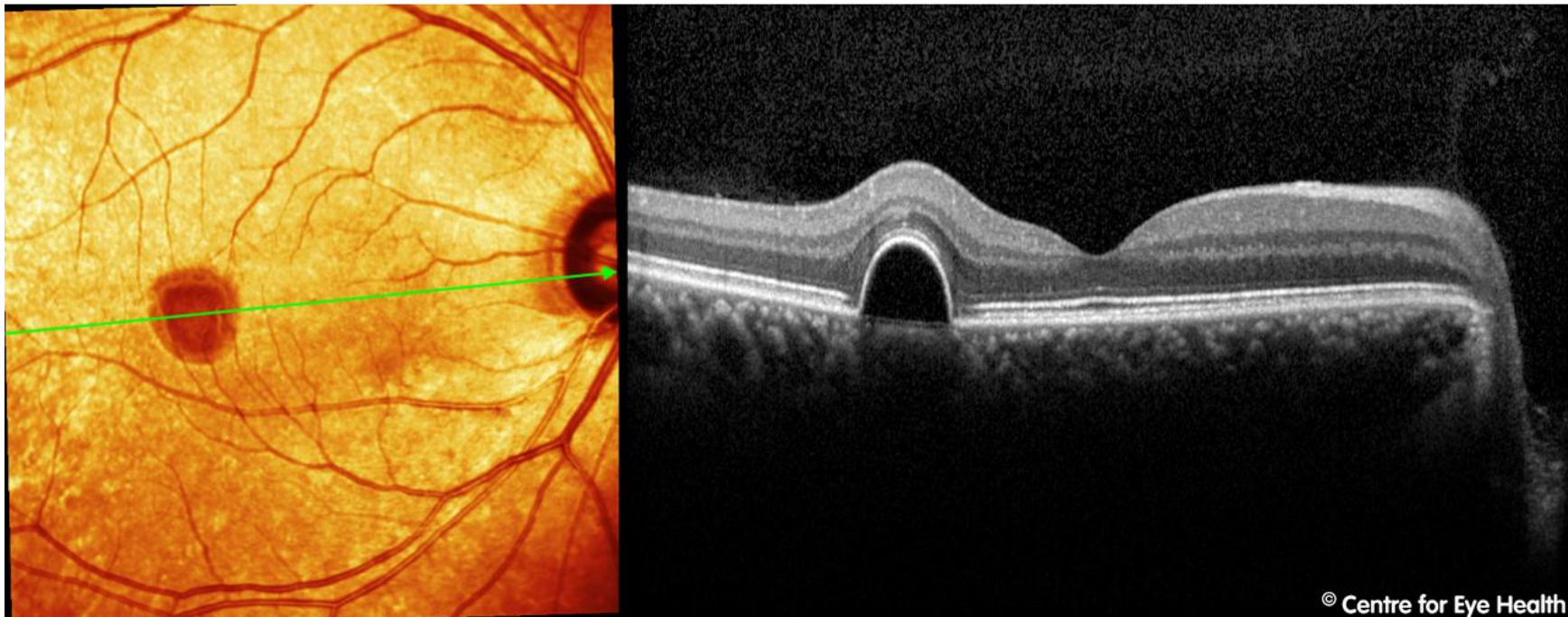




## CFEH Facebook Case #74

A 49 year old Asian male presented to the Centre 6 months ago for macular tests. An OCT of the right macula is below. What management was undertaken and what do you expect the OCT show today?



© Centre for Eye Health

Proudly brought to you by

**LEARNING & VISION**



Centre for Eye Health



Optometry  
NEW SOUTH WALES  
AUSTRALIAN CAPITAL TERRITORY

Proudly brought to you by

**LEARNING FOR VISION**



Centre for Eye Health



Optometry  
NEW SOUTH WALES  
AUSTRALIAN CAPITAL TERRITORY

# ANSWER

The patient was referred to an ophthalmologist who elected to monitor the serous pigment epithelial detachment (PED) for the development of choroidal neovascularisation. When he was referred back to the Centre for follow up scans after 6 months, the PED had almost completely resolved leaving little sign that it had ever been there aside from a mild thinning of the RPE layer, slight loss of reflectivity of the ISe line and subtle irregularities in the spectral reflectance map (left).

