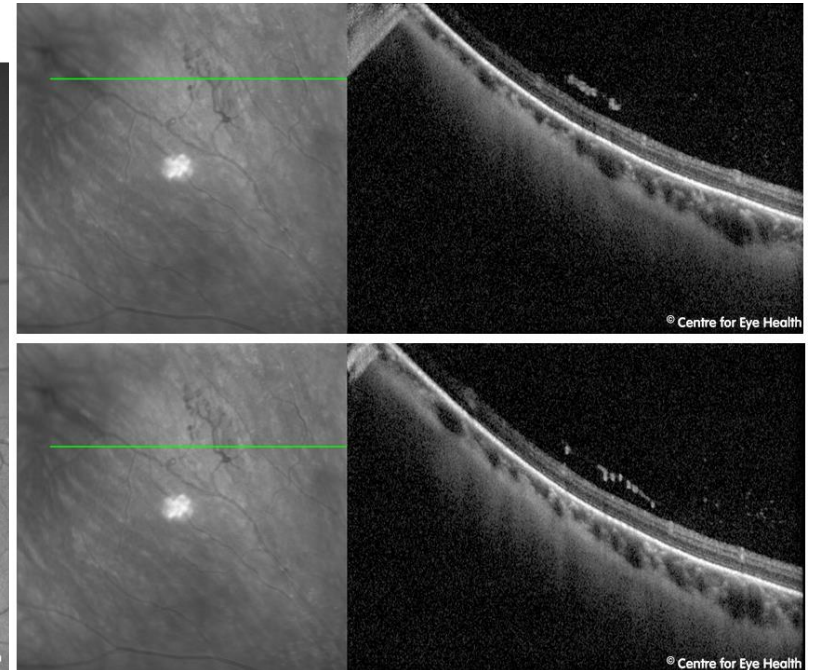
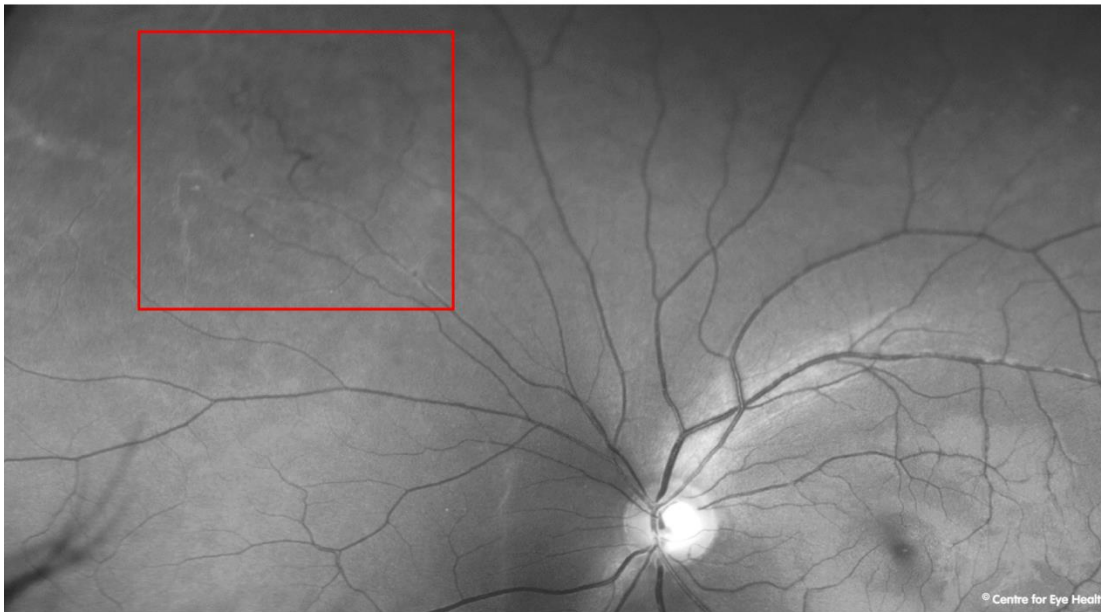



## CFEH Facebook Case #127

A 35 year old male presented for a glaucoma assessment based on suspicious discs. He reports good general health but slightly elevated blood sugar levels at a recent checkup. His best corrected acuities were 6/4.8 in each eye. Imaging revealed some unusual vascular changes peripherally in the left eye. What is the vascular change and what would be your management of this patient?



## ANSWER

Imaging shows neovascularisation, unusual vessel looping and arteriolar sheathing in the superonasal peripheral retina of the left eye. An OCT scan through this area reveals neovascularisation at the posterior vitreous interface.

These changes indicate a likely systemic cause, however this is not immediately identifiable from an ocular examination alone. The patient was referred to an ophthalmologist and a full systemic workup recommended.