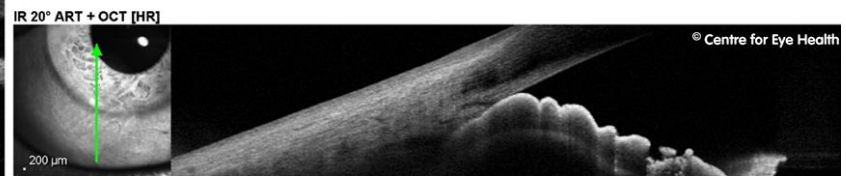
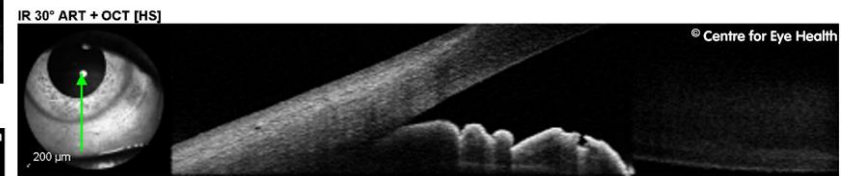
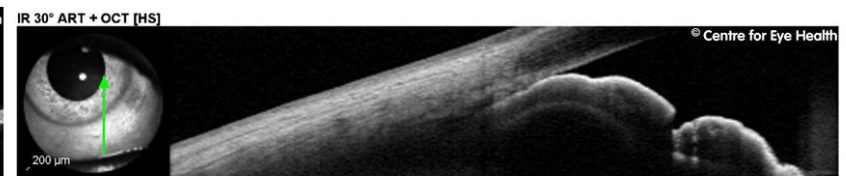
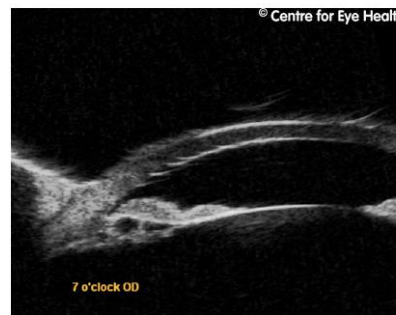
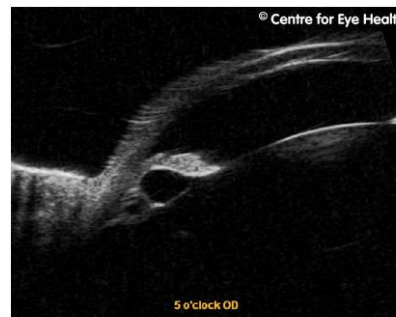
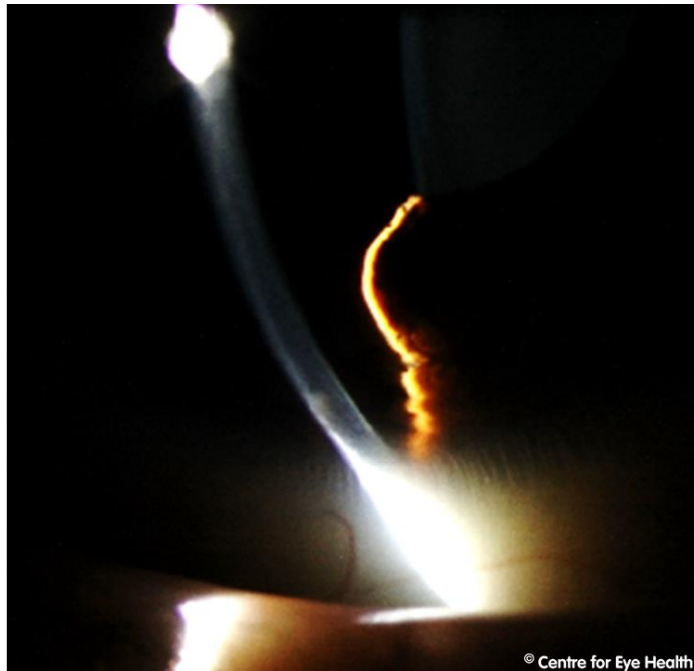## CFEH Facebook Case #115

A 41 year old female presented for assessment of multiple inferior iris lesions around 5 and 7 o'clock. No pupil distortion was noted. The patient is asymptomatic, reports good general health and takes no medications. What is your diagnosis and management for this patient?



# ANSWER

The anterior OCT images show closing of the anterior chamber angle in the inferior region caused by the forward bowing of the inferior iris lesions. Examination with ultrasound biomicroscopy showed multiple cysts arising from the iris pigment epithelium from 5 to 7 o'clock in the right eye. The cysts are characterized by sonoluscent fluid within a thin and highly reflective wall.

While primary iris pigment epithelial cysts are usually stationary, in this case the size and location of the cysts have given rise to significant bowing and obstruction of the inferior angle. Consequently regular monitoring was recommended for this patient, with gonioscopy to be performed annually.