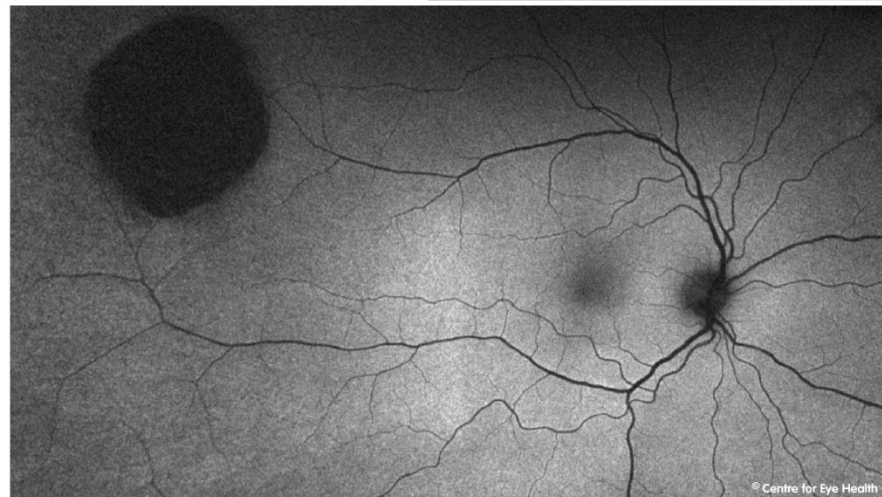
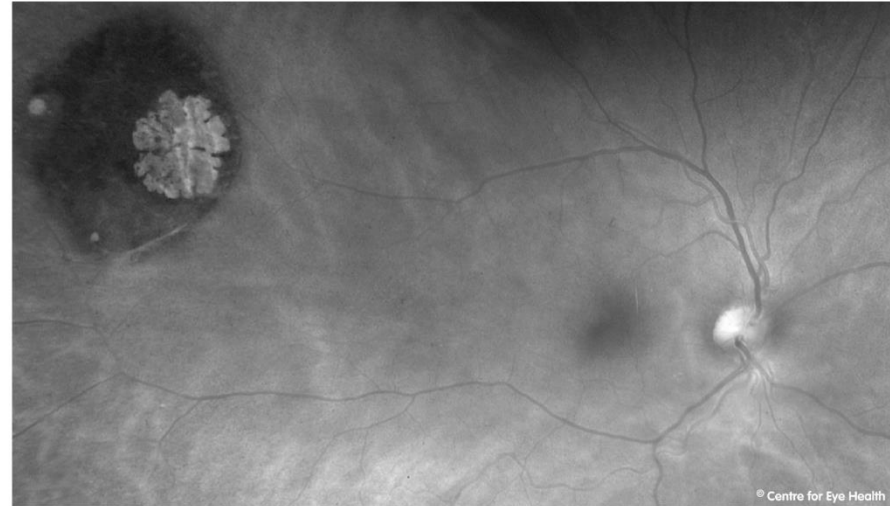
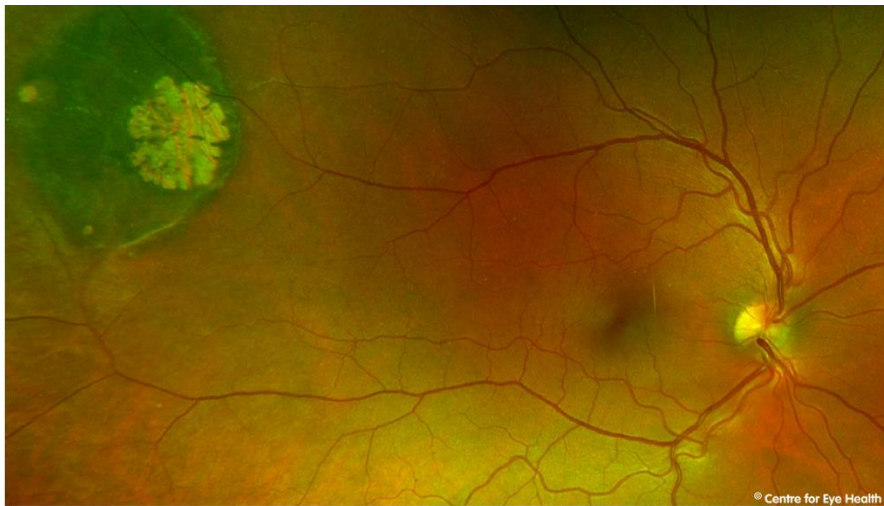
CFEH Facebook Case #110

A 46 year old female presented for an assessment of a peripheral lesion. She was healthy, asymptomatic and vision was 6/6 in both eyes. Optomap, red free and fundus autofluorescence images of the lesion are below. Identify the lesion seen in this patient and also the appropriate management.



Proudly brought to you by

LEARNING & VISION



Centre for Eye Health



Optometry
NEW SOUTH WALES
AUSTRALIAN CAPITAL TERRITORY

Proudly brought to you by

LEARNING FOR VISION



Centre for Eye Health

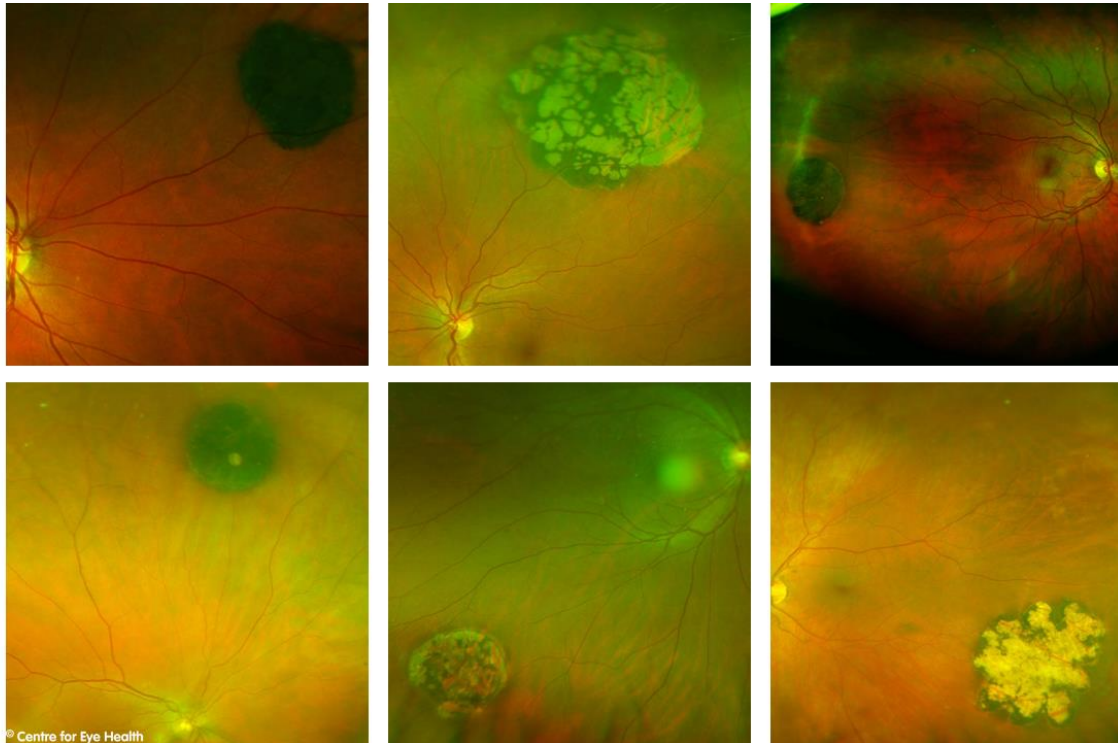


Optometry
NEW SOUTH WALES
AUSTRALIAN CAPITAL TERRITORY

ANSWER

CHRPE with internal atrophy (lacunae)

CHRPE are benign lesions, usually flat round and heavily pigmented. Approximately half of all CHRPE's contain lacunae, or window-like defects of atrophy that are contained within the lesion such as in this case. These lacunae typically increase in size and also number over time, leading to a wide variety of different possible presentations. Some examples are seen below:



Routine review of these lesions are recommended. For more information on diagnosing retinal lesions, please see our pigmented and hypo-pigmented lesions chairside references, downloadable from our website: <https://centreforeyehealth.com.au/chairside-references/>

