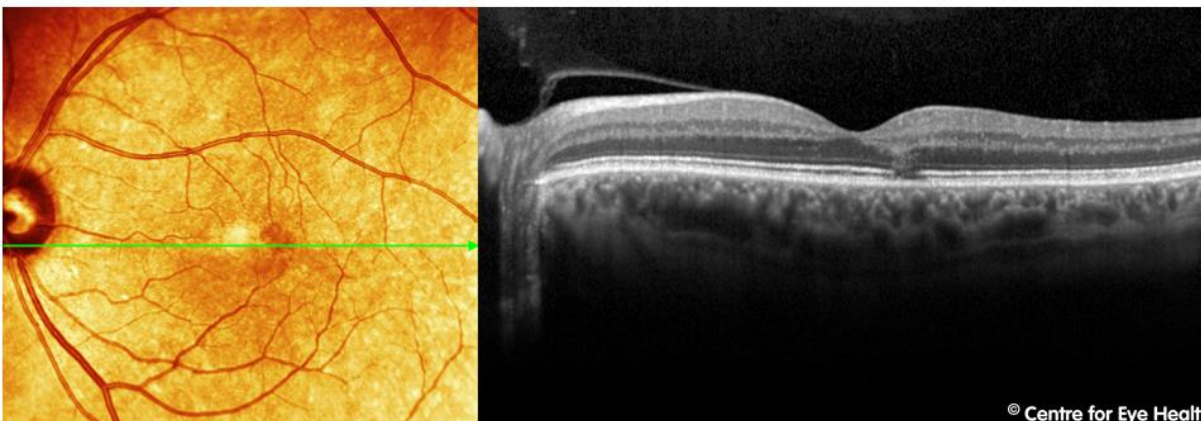
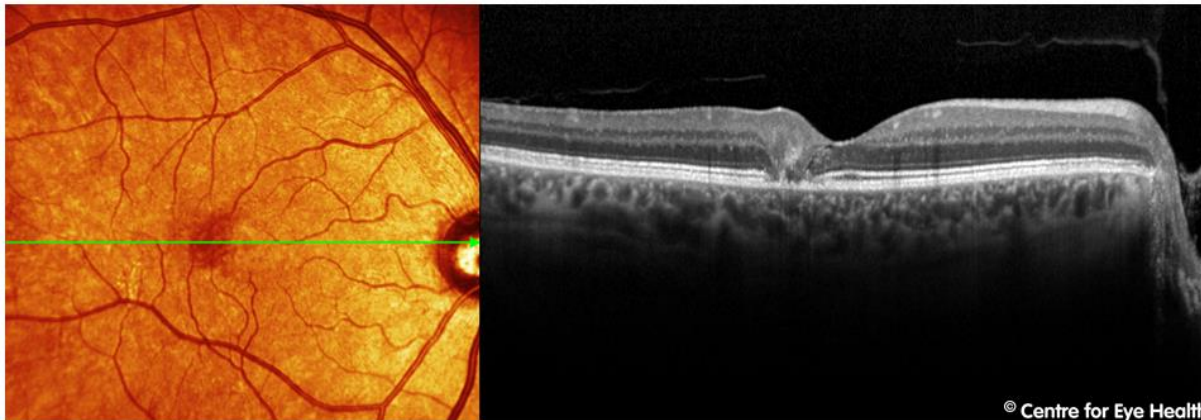




CFEH Facebook Case #41

A 64 year old male was sent to CFEH for a macular assessment after his optometrist noticed some pigment changes at the right macula. He suffers from diabetes and hypercholesterolemia but reports both to be well controlled with medication. BCVA 6/6 OU. Amsler grid testing revealed some distortion 4-5 degrees nasal to fixation in the right eye and 3 degrees nasal to fixation in the left. OCT line scans through the central fovea are shown. What is the likely cause of the distortion and pigment change?



Proudly brought to you by
LEARNING FOR VISION



Proudly brought to you by

LEARNING FOR VISION



ANSWER

Macular Telangiectasia type 2 (Mac Tel 2), stage 2.

The OCT image in the right eye shows disruption of the outer retinal layers with some cystic spaces at the nasal aspect of the lesion. The RPE/Bruchs membrane complex is very irregular in the affected region and the pigment plaque in this eye corresponds with increased intraretinal reflectivity. Looking at the left macular OCT, there is also some disruption of the outer retinal layers, including disruption of the ellipsoid zone.

Mac Tel 2 is a bilateral perifoveal vasculopathy of unknown cause, however a genetic component to this disease is highly likely. Prevalence is 0.1% of the general population. Symptoms typically start in the 5th or 6th decade of life and the early signs may be very subtle.

Signs and symptoms are typically limited to mildly reduced visual acuity and metamorphopsia, both of which are subtle at first but increase as the disease progresses. Typical clinical findings include a dulling or loss of the foveal reflex, a greying of the parafoveal area, small foveal cystoid changes and pigment clumping. A pseudo-vitelliform lesion can also form in the central macula.

Fundus autofluorescence imaging can also be useful in evaluating MacTel 2. Areas of photoreceptor atrophy appear hyperfluorescent when a pseudovitelliform lesion develops and RPE atrophy appears hypofluorescent. The normal central attenuation of FAF may be lost in eyes with MacTel2.

The literature identifies 5 stages of the disease process with stage 5 (proliferative stage) characterised by the formation of subretinal neovascularisation. This stage is accompanied by retinal oedema, yellow exudates, subretinal / intraretinal haemorrhages and, over time, retinal fibrosis.

There is no treatment for the pre-proliferative stages, however photodynamic therapy may be useful in decreasing vision loss in the proliferative stages.

