

CFEH

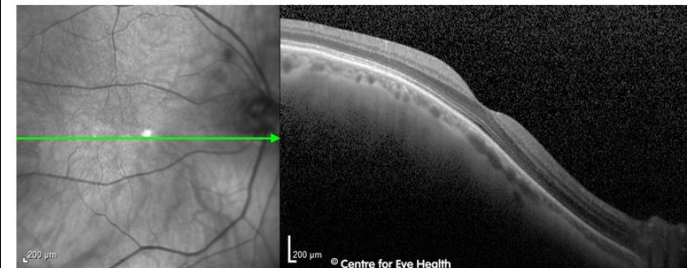
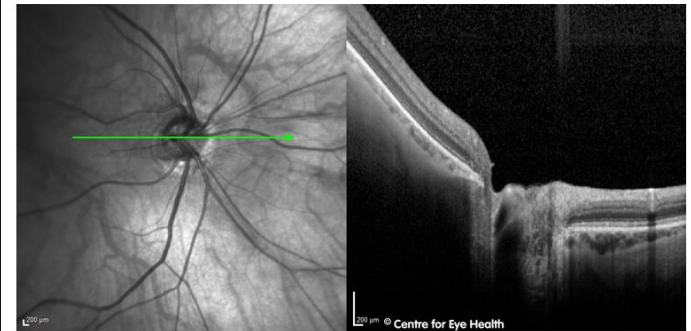
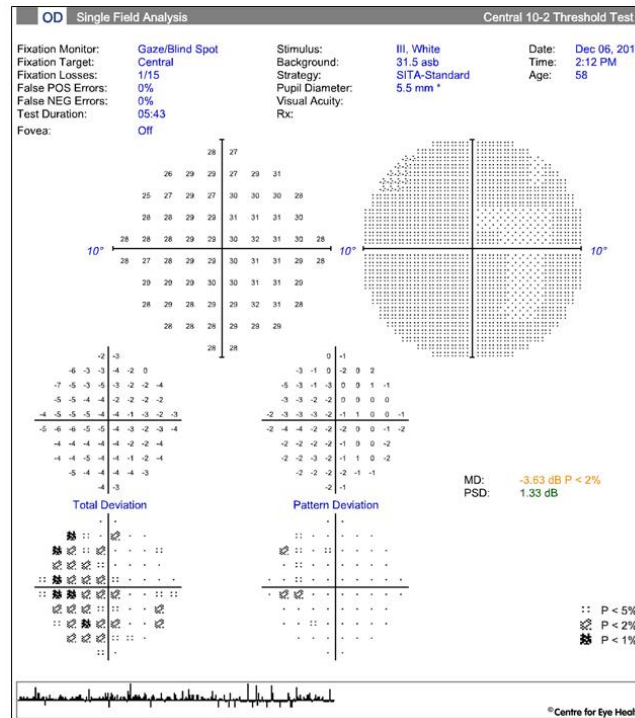
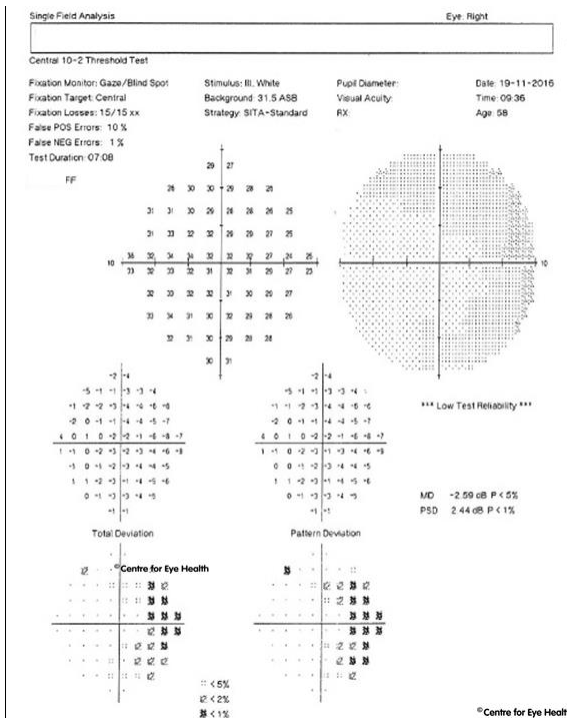
facebook



Cases

CFEH Facebook Case #39

A 58 year old Caucasian female presented to the Centre for a retinal examination as she has been taking Plaquenil (200mg/day) for 9 months. She is a former smoker, having quit 10 years ago. The prescription in her right eye is -6.00 DS and left -2.25 DS. The left eye was unremarkable so this case will focus on the right. A 10-2 right visual field was performed twice (2 weeks apart). What did the CFEH optometrist do to make the apparent temporal field depression appear to reverse, and why did this happen? OCT images are included to help you answer.



Proudly brought to you by
LEARNING FOR VISION



Proudly brought to you by

LEARNING FOR VISION



Centre for Eye Health



Optometry
NEW SOUTH WALES
AUSTRALIAN CAPITAL TERRITORY

ANSWER

This patient has a nasal staphyloma as seen in the OCT image. With her prescription which corrects for her foveal vision in place – as typically recommended by the instrument’s algorithm - the light falling on the nasal retina would be defocussed as the retinal plane is bowed posteriorly in the region of the staphyloma (by definition). This has caused a corresponding apparent temporal field depression in the initial visual field examination.

Upon re-examination, an additional -2.00DS was added to the patient’s prescription for the purposes of the field test. This focussed the light more accurately in the area of the staphyloma, as the light rays are more diverged, causing the apparent temporal depression to disappear. However the light falling on the temporal (non-staphylomatous) retina is now defocussed, with light rays *too* divergent for the retinal plane in this region, causing an apparent nasal field depression instead.

Thus, a simple increase in myopic correction to correct for different retinal planes has caused an apparent reversal of the field defect. One differential for a temporal field defect such as was seen on initial examination would be a chiasmal lesion. Demonstration of reversal of a field defect such as in this case, would suggest that that defect is likely to be optical in origin rather than pathological.