

CFEH Facebook Case #11

A 47 year old Caucasian female was referred to the Centre for further investigation of a lesion in the left eye detected on routine examination. She did not report any visual symptoms. Her ocular history and medical history are unremarkable. There was no significant family history of eye conditions.

Best corrected acuities were 6/6 OD and 6/6-1. Amsler grid revealed no distortions for the right eye but distortion was noted in the inferonasal field of the left eye. A slitlamp examination of the anterior eye was unremarkable for both eyes. As the right eye appearance was normal, this case will focus on the left eye only. Colour and red-free fundus photos, left visual field, fundus autofluorescence and an OCT through the lesion are included below.

What is your diagnosis and management?

Proudly brought to you by
LEARNING FOR VISION



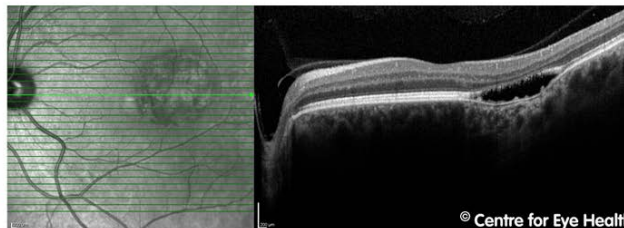
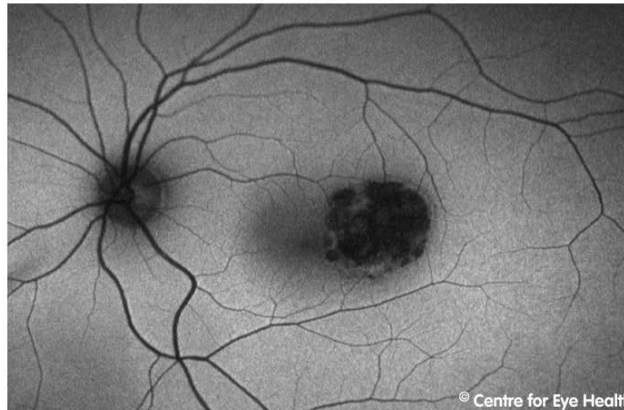
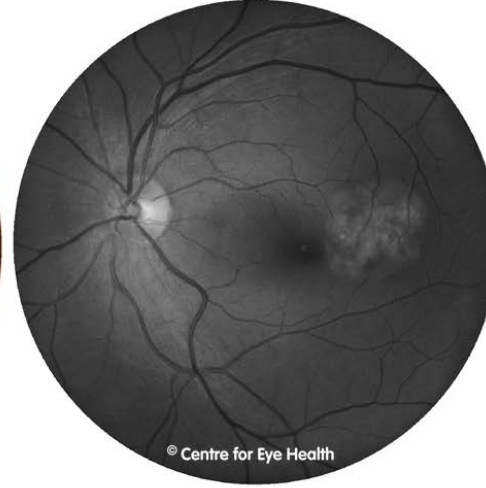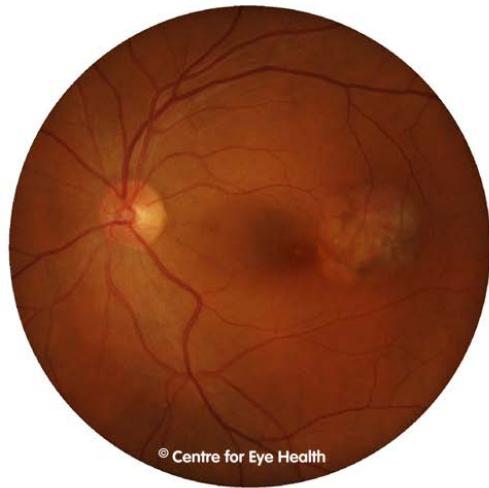Centre for Eye Health



Optometry

NEW SOUTH WALES

AUSTRALIAN CAPITAL TERRITORY





Central 10-2 Threshold Test



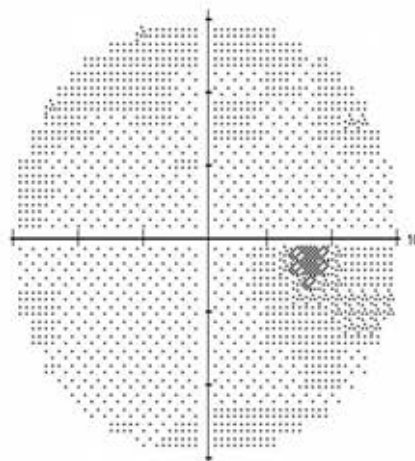

Fixation Monitor: Gaze/Blind Spot
 Fixation Target: Central
 Fixation Losses: 0/17
 False POS Errors: 0 %
 False NEG Errors: 5 %
 Test Duration: 05:57

Stimulus: Ill. White
 Background: 31.5 ASB
 Strategy: SITA-Standard



Pupil Diameter: 6.2 mm
 Visual Acuity:
 RX: +3.25 DS DC X

Date: 11-10-2012
 Time: 9:12 AM
 Age: 47

Fovea: OFF



MD -2.40 dB P < 5%
 PSD 3.27 dB P < 1%



:: < 5%
 < 2%
 < 1%

ANSWER

Torpedo maculopathy with corresponding Amsler grid distortion and visual field loss inferonasally

Torpedo maculopathy is a congenital, solitary, chorioretinal lesion. There are no known associated congenital, systemic or ocular abnormalities. Distinctive features of torpedo maculopathy include a location temporal to the fovea, hypopigmentation and a horizontally oval, spindle-shaped lesion resembling a torpedo. This lesion typically has a pointed "head" directed toward the fovea and a round or frayed tail at the temporal margin.

Visual acuity is generally not affected as the lesion does not involve the central fovea. As in this case, visual fields testing with 10-2 threshold perimetry showed a corresponding inferonasal defect. Amsler grid can be used as a screening assessment however it should be noted this may be less sensitive to smaller lesions.

OCT imaging shows a neurosensory retinal detachment with a large cleft (posterior detachment of the RPE) and attenuation of the outer retinal layers including the inner segment ellipsoid line and RPE. The choroid is also more visible in the area of the lesion.

Fundus autofluorescence imaging of the lesion reveals a predominantly dense hypo-autofluorescence pattern with mottled areas of iso- or hyper-autofluorescence.

In terms of management for this case, although the lesion is congenital in nature and not known to progress, it is still important to establish stability and monitor progression particularly considering its proximity to the fovea. Therefore, routine review with photographic documentation for comparison and repeat imaging with OCT is recommended. It is also worthwhile for the patient to self-monitor their symptoms with the Amsler grid and patients should be advised to seek medical attention should any new or change in symptoms arise.