

CFEH Facebook Case #18

A 27 year old male presented to CFEH for assessment of his anterior eye. He reported a “ghosting” of the vision in his left eye which he noticed only when wearing spectacles. Best corrected acuities were 6/6 in the right eye and 6/9.5 in the left. Refraction was as below:

RE: -0.25 / -0.25 x 8

LE: -1.50 / -2.25 x 78

A slit lamp image of the left eye is below. The changes photographed are only on the superior cornea with the inferior appearing normal and the right eye showed similar but less pronounced changes.

What further test would you require and what is the most likely diagnosis?

Proudly brought to you by
LEARNING FOR VISION



Centre for Eye Health



Optometry

NEW SOUTH WALES

AUSTRALIAN CAPITAL TERRITORY

Proudly brought to you by

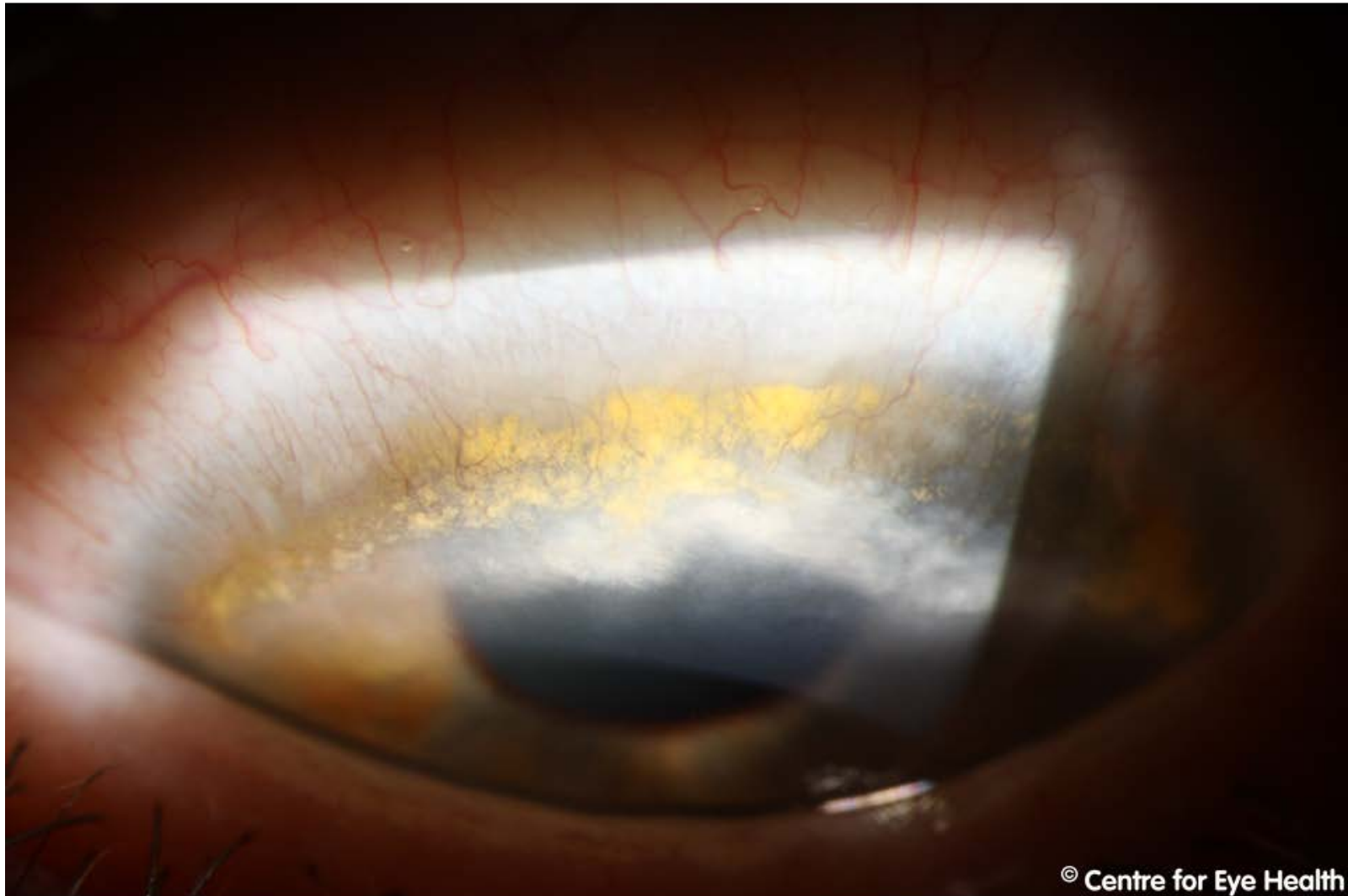
LEARNING FOR VISION



Centre for Eye Health



Optometry
NEW SOUTH WALES
AUSTRALIAN CAPITAL TERRITORY



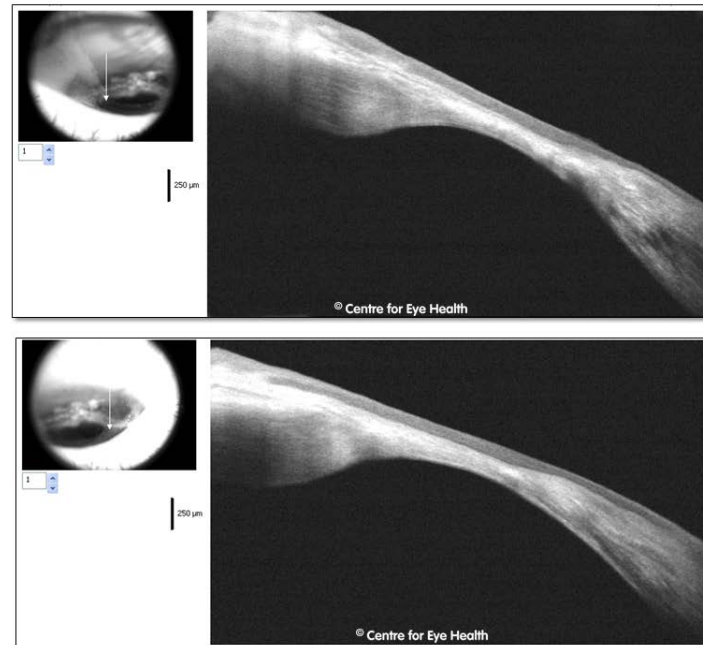
© Centre for Eye Health

ANSWER

Terrien's marginal degeneration

The slit lamp images show fine, superficial vascularization extending from the limbus, irregular yellow lipid deposits and corneal opacification/scarring.

Anterior OCT images (below) show thinning of the cornea with a thickness measurement in the lower scan of just 213µm



Terrien's marginal degeneration typically shows superior thinning of the cornea with associated lipid deposit and neovascularization. Those with this condition often have reduced vision associated with against the rule astigmatism. The corneal epithelium remains intact in this condition, so the area will not stain with fluorescein.

There are two types of presentation. The first is a non-inflammatory type that typically presents in males over 40 years of age and has a slow rate of progression. The second is associated with episcleral and scleral inflammation and presents in patients aged 20-30 years of age. This second type has a more guarded prognosis with patients at risk for corneal perforation (particularly following trauma) which would require lamellar keratoplasty. Considering this risk, the patient was referred to ophthalmology.