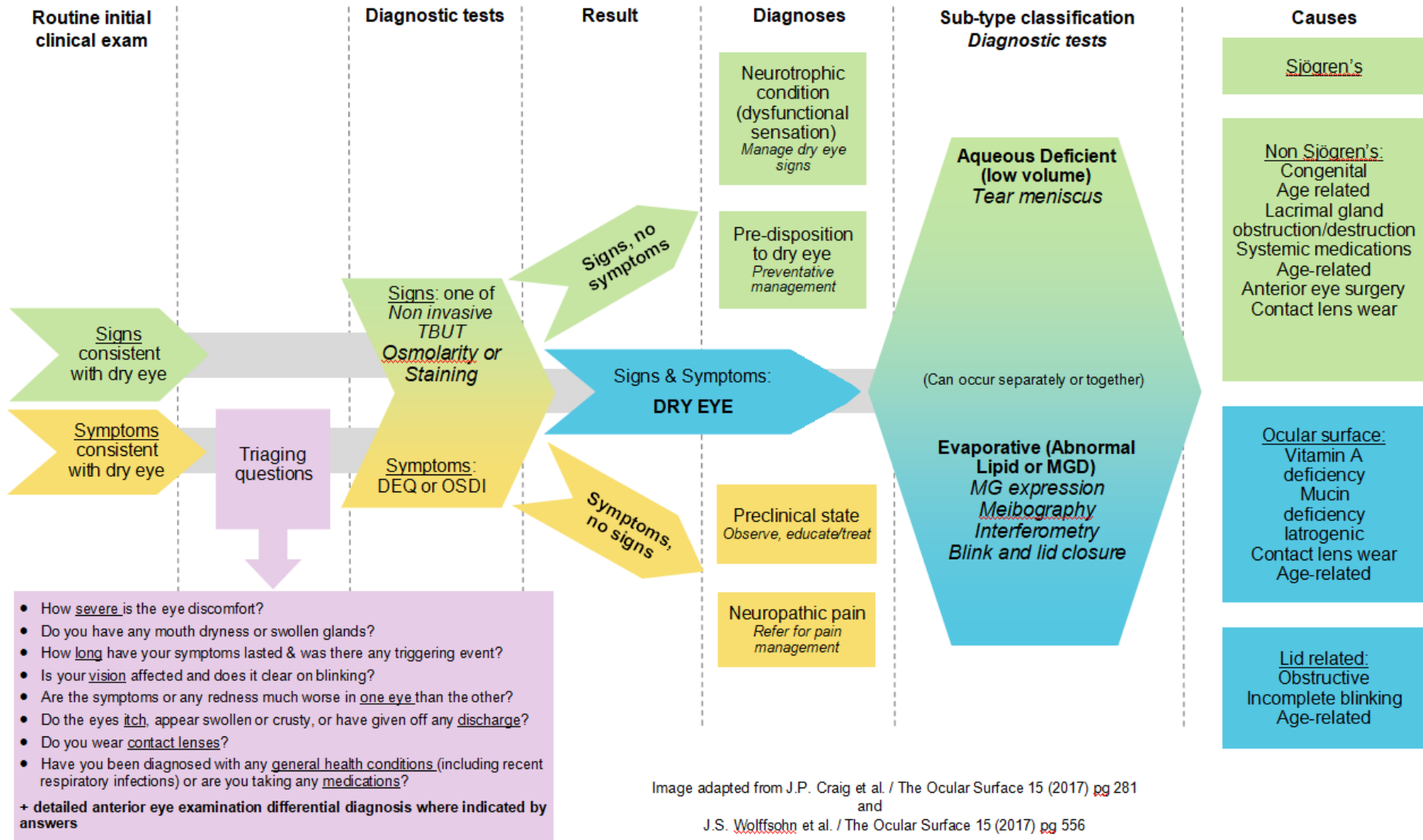


## Dry Eye Definition: TFOS DEWS II

Dry eye is a multifactorial disease of the ocular surface characterised by a loss of homeostasis of the tear film and accompanied by ocular symptoms in which tear film instability and hyperosmolarity, ocular surface inflammation and damage, and neurosensory abnormalities play aetiological roles.

### Examination and differential diagnosis workflow



Risk Factors: Modifiable			Risk Factors: Non-Modifiable		
Consistently shown	Probable	Inconclusive	Consistently shown	Probable	Inconclusive
Androgen deficiency Computer use CL wear Hormone replacement therapy Haematopoietic stem cell transplantation Environment (pollution, low humidity)	Low intake of FFA Refractive Surgery Allergic Conjunctivitis	Smoking Alcohol Pregnancy Demodex Botox injection	Age Female Asian MGD Connective tissue disorder Sjögren’s syndrome	Diabetes Rosacea Viral infection Thyroid disease Psychiatric conditions Pterygium	Hispanic Menopause Acne Sarcoidosis
<b>Medications</b>					
Antihistamines, Antidepressants, Anxiolytics, Isotretinoin	Anticholinergics, Diuretics, Beta-blockers	Multivitamins / Oral contraceptive			

## TFOS DEWSII staged management and treatment recommendations

Notes: 1. These steps are not designed to be a rigid, fixed process, but more an organisational tool  
 2. Options within a step are not ranked by importance  
 3. It is possible and likely that one or more option within each step will be needed/utilised  
 4. Earlier steps should be continued if moving to higher steps

### STEP 1

Education Modification of local environment Dietary modifications including oral essential fatty acid supplementation	Identify and potentially modify offending systemic and topical medications Ocular lubricants of various types: if MGD is present, then consider lipid containing supplements Lid hygiene and warm compresses of various types
---	---

### STEP 2

Non-preserved ocular lubricants Tea tree oil treatment for Demodex (if present) Tear conservation (Punctal occlusion / Moisture chamber goggles) Overnight treatments (ointment or moisture chamber devices) In-office, physical heating and expression of the meibomian glands (including device-assisted therapies) In-office intense pulsed light therapy for MGD	Prescription drugs to manage dry eye disease Topical antibiotic or antibiotic/steroid combination applied to the lid margins for anterior blepharitis (if present) Topical corticosteroid (limited-duration) Topical secretagogues Topical non-glucocorticoid drugs (such as cyclosporine) Topical LFA-1 antagonist drugs (such as Lifitegrast) Oral macrolide or tetracycline antibiotics
---	--

### STEP 3

Oral secretagogues Autologous/allogeneic serum eye drops Therapeutic contact lens options Soft bandage lenses Rigid scleral lenses	STEP 4 Topical corticosteroid for longer duration Amniotic membrane grafts Surgical punctal occlusion Other surgical approaches: tarsorrhaphy, salivary gland transplantation
--	---