



Visual field examination, in particular, standard automated perimetry, remains the most commonly utilised functional assessment. Many ocular and neurological diseases and conditions are known to exhibit distinct visual field loss patterns, and thus, visual field testing may therefore assist with a differential diagnosis. The ability to map the depth, extent and change of visual field defects should be considered in clinical management decisions. The more common types of visual field defects and their differentials are outlined below.

Results must be interpreted critically (reliability and repeatability) and in conjunction with other clinical signs, symptoms and examination findings.

Vertical Field Loss Pattern

Vertically oriented field defects should always raise the suspicion of pathologies on the visual pathway beyond the retina, particularly if it respects the vertical midline.

Differentials:

- Unilateral:*
- Retinal disease
 - Pre-chiasmal or anterior chiasmal lesion (e.g. compressive lesions)

Bilateral (homonymous):

- Post-chiasmal lesion (e.g. compressive lesions, stroke, injuries)


Bilateral (bitemporal/binasal):

- Chiasmal lesions (pituitary adenoma, meningioma, parasellar carotid artery aneurysm, meningioma, craniopharyngioma, glioma)
- Tilted disc

Vertical field loss can be classified into the following patterns:

1. Vertical Step:

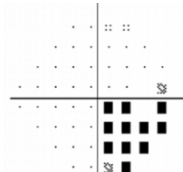
Generally respects the vertical midline with at least 2 points outside 15° of fixation.



2. Quadrant:

Visual field loss that respects both the vertical & horizontal midline. Suggestive of neurological involvement if bilateral. All points within the quadrant must be P<5%.

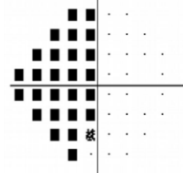
Note: Pituitary gland adenoma gives more superior defects ("pie-in-the-sky") while parasellar lesions give more inferior losses ("pie-on-the-ground").



3. Hemianopia:

Loss of the vertical hemifield respecting the vertical midline either partially or completely.

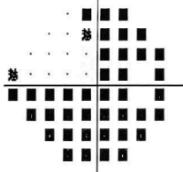
Note: Monocular temporal hemianopia may occur if the lesion is more anterior and only affecting the nasal crossing fibres from the ipsilateral eye.



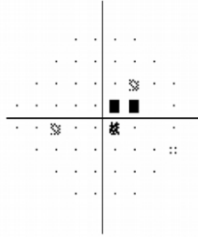
4. Three Quadrants:

Three quadrants with all points at least P<5%. Partial three quadrant losses does not have all points P<5% but is greater than a complete hemianopia.

Note: Multiple lesions or pathologies may need to be considered.



Centrocecal

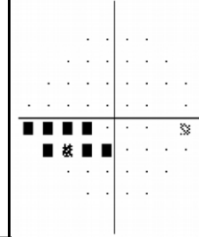


Description: Field loss extending from blindspot to fixation. Must include fixation and does not obey horizontal midline. Usually due to damage of the papillomacular bundle.

Differentials:

- Optic neuritis
- NAION/AION
- Cilioretinal artery occlusion
- Macular disease
- Retinal disease

Nasal Step

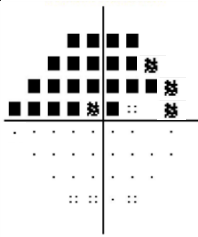


Description: Field loss respecting the nasal horizontal midline with at least 1 abnormal point outside 15°. No more than 1 point may be on the temporal side.

Differentials:

- Glaucoma
- Papilloedema
- Optic nerve drusen
- Optic neuritis
- High myopia
- Retinal disease

Altitudinal

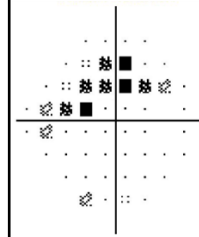


Description: Field loss that respects the horizontal midline.

Differentials:

- Branch retinal artery/vein occlusion
- NAION/AION
- Retinal disease
- Advanced glaucoma
- Cortical disease (if bilateral, rare)

Arcuate

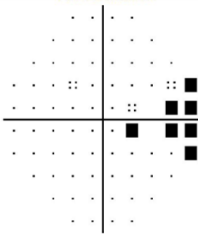


Description: Field loss extending from the blind spot to the nasal field with at least one point outside 15° nasally and at least one abnormal point temporally.

Differentials:

- Glaucoma
- Papilloedema
- Optic nerve drusen
- Optic neuritis
- High myopia
- Branch retinal artery/vein occlusion
- Retinal disease

Temporal Wedge

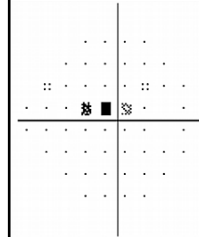


Description: Small visual field defect temporal to blind spot.

Differentials:

- Optic neuritis
- Glaucoma (rare)
- Retinal disease

Paracentral

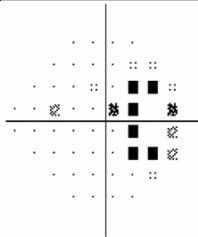


Description: A small visual field abnormality not contiguous to the blind spot and within 15° of fixation.

Differentials:

- Glaucoma
- Papilloedema
- Optic nerve drusen
- Optic neuritis
- High myopia

Enlarged Blind Spot




Description: Visual field loss involving at least two points contiguous to the blind spot.

Differentials:

- Papilloedema
- Glaucoma (rare)
- Large peripapillary atrophy
- Optic disc drusen
- Optic nerve coloboma
- Staphyloma
- Megalopapillae
- Tilted disc syndrome

Clover Leaf



Description: Diagonal paracentral points show normal or near-normal sensitivity but all other points reduced. This is often due to patient responding normally at the start of the test only as the visual field instrument generally test these points first. Often accompanied by high fixation loss and false negative.

Differentials:

- Inattentive patient
- Poor supervision
- Malingering
- Retinal disease

Structure/Function

The relationship between the retinal nerve fibre layer location and corresponding visual field is complex due to significant individual variations (Lamparter et al. 2013). The following shows a 'typical' structure/function relationship for the right eye adapted from Ferreras et al. 2008

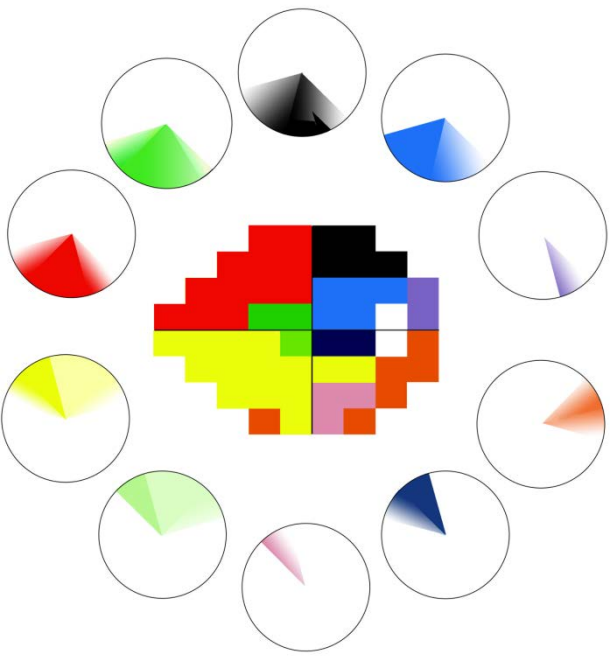


Figure 1. A map showing the relationship between RNFL sectors and test points on a 24-2 field test adapted from Ferreras et al. *IOVS* 2008.

Visual Pathway

There are many ocular and neurological conditions that can lead to field defects with the following diagram showing the possible location of a visual pathway defect based on the pattern of field loss.

- Note, however, that:
- field loss often does not precisely follow the pattern as outlined below;
 - partial losses or losses that are not entirely symmetrical are common.

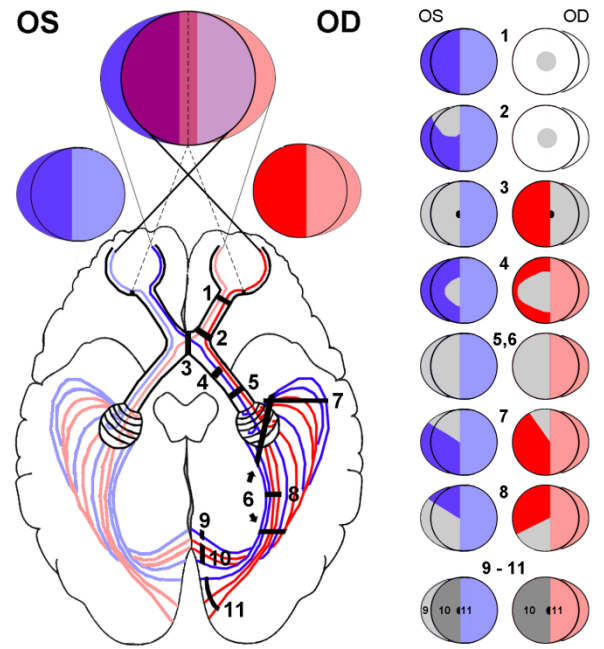


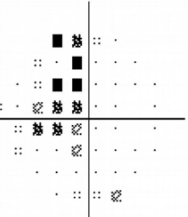
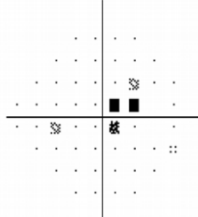
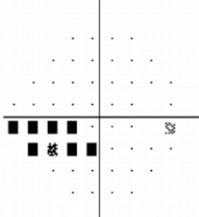
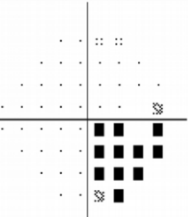
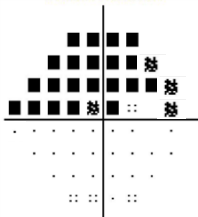
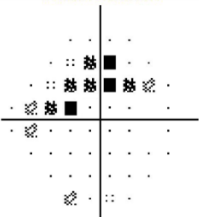
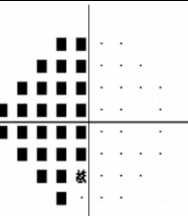
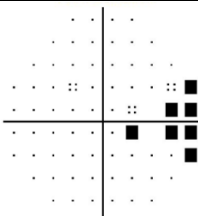
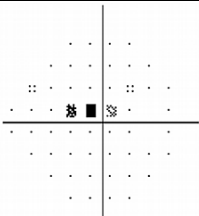
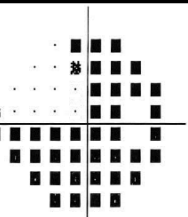
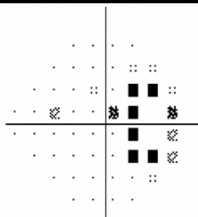

Figure 2. A diagram showing the visual pathway and field loss that may result from different injuries. Grey denotes scotoma on the right hand diagrams. (Zangerl et al *Clin Exp Optom* 2017)

Clinical Pearls

- Reliability:**
- Unless there is a correlating structural finding, field defects need to be repeatable before they can be considered to be clinically significant due to large variability, especially in the periphery.
 - Visual field measurement errors generally result in falsely low sensitivity rather than falsely high (Heijl et al. 1987).
 - False positive errors have a greater effect on visual field reliability than the fixation loss or false negative errors.
 - Increased false negative errors is correlated with the severity of visual field loss, even with reliable visual field takers (Bengtsson and Heijl 2000).
 - In the presence of severe temporal field defects or micropapillae, blindspot based fixation monitoring is generally ineffective, and other forms of fixation monitoring such as gaze-monitoring and practitioner observation needs to be used instead
- Interpretation**
- A visual field area with "complete loss" (<0dB for Humphrey's field) is not necessarily completely blind. A target with a greater luminance or size may still be visible.
 - As blindspots are generally 6 degrees in size, blindspot based fixation monitoring cannot detect fixation loss less than 3 degrees (which equates to half the distance between test locations for 24/30-2). On the contrary, eye movement monitoring technique can record fixation loss as small as 1 degree. Thus, this should be considered in conjunction with the traditional reliability method when interpreting visual field. (Ishiyama et al. 2015)
- Glaucoma:**
- In glaucoma, either structural loss or functional loss can occur first depending on the sensitivity of the devices used to detect the loss (Keltner et al. 2006).
 - Central field loss may be seen in as many as 50% of glaucoma cases (Schiefer et al. 2010) and thus, a 10-2 field or equivalent may be useful.
 - 24-2 is designed for glaucoma assessment; if a non-glaucomatous defect is suspected, utilise a 30-2 instead.



Visual field examination, in particular, static automated perimetry, remains the most commonly utilised functional assessment of the extra-foveal visual system. Many ocular and neurological diseases and conditions are known to exhibit distinct visual field loss patterns, and thus, testing may assist with a differential diagnosis. The ability to map the depth, extent and change of visual defects also enables assessment of a patient's peripheral vision to make informed clinical management decisions. The more common types of visual field defects and their differentials are outlined below. Results must be interpreted critically (reliability and repeatability) and in conjunction with other clinical signs, symptoms and examination findings.

<p>Vertical Step</p>  <p>Description: Generally respects the vertical midline with at least 2 points outside 15° of fixation. Differentials: <i>Unilateral:</i> Retinal, pre-chiasmal or anterior chiasmal lesion (e.g. compressive lesions) <i>Bilateral (Homonymous):</i> post-chiasmal lesion (e.g. compressive lesions, strokes, injuries) <i>Bilateral (bitemporal/binasal):</i> chiasmal lesions (pituitary adenoma, meningioma, parasellar carotid artery aneurysm, meningioma, craniopharyngioma, glioma), tilted disc.</p>	<p>Centrocecal</p>  <p>Description: Field loss extending from blindspot to fixation. Must include fixation and does not obey horizontal midline. Usually due to damage of the papillomacular bundle. Differentials: <ul style="list-style-type: none"> Optic neuritis Cilioretinal artery occlusion NAION/AION Macular disease Retinal disease </p>	<p>Nasal Step</p>  <p>Description: Field loss respecting the nasal horizontal midline with at least 1 abnormal point outside 15°. No more than 1 point may be on the temporal side. Differentials: <ul style="list-style-type: none"> Glaucoma Papilloedema Optic nerve drusen Optic neuritis High myopia Retinal disease </p>
<p>Quadrant</p>  <p>Description: Visual field loss that respects both the vertical & horizontal midline. Suggestive of neurological involvement if bilateral. All points within the quadrant must be P<5%. Differentials: As for vertical step. Note that pituitary gland adenoma gives more superior defects ("pie-in-the-sky") while parasellar lesions give more inferior losses ("pie-on-the-ground").</p>	<p>Altitudinal</p>  <p>Description: Field loss that respects the horizontal midline Differentials: <ul style="list-style-type: none"> Branch retinal artery/vein occlusion NAION/AION Cortical disease (if bilateral, rare) Retinal disease Advanced glaucoma </p>	<p>Arcuate</p>  <p>Description: Field loss extending from the blind spot to the nasal field with at least one point outside 15° nasally and at least one abnormal point temporally. Differentials: <ul style="list-style-type: none"> Glaucoma Papilloedema Optic nerve drusen Optic neuritis High myopia Branch retinal artery/vein occlusion Retinal disease </p>
<p>Hemianopia (complete or partial)</p>  <p>Description: Loss of the vertical hemifield respecting the vertical midline, partially or completely. Differentials: As for vertical step. Bitemporal hemianopia results from compromised nasal fibres of the optic nerves of both eyes due to injuries or lesions at the optic chiasm. Monocular temporal hemianopia may occur if the lesion is more anterior and only affecting the nasal crossing fibres from the ipsilateral eye.</p>	<p>Temporal Wedge</p>  <p>Description: Small visual field defect temporal to blind spot. Differentials: <ul style="list-style-type: none"> Optic neuritis Glaucoma (rare) Retinal disease </p>	<p>Paracentral</p>  <p>Description: A small visual field abnormality not contiguous to the blind spot and within 15° of fixation Differentials: <ul style="list-style-type: none"> Glaucoma Papilloedema Optic nerve drusen Optic neuritis High myopia </p>
<p>Three Quadrant (complete or partial)</p>  <p>Description: Three quadrants with all points at least P<5%. Partial three quadrant losses does not have all points P<5% but is greater than a complete hemianopia. Differentials: As for vertical step. Multiple lesions or pathologies may also need to be considered.</p>	<p>Enlarged Blind Spot</p>  <p>Description: Visual field loss involving at least two points contiguous to the blind spot. Differentials: <ul style="list-style-type: none"> Papilloedema Glaucoma (rare) Large peripapillary atrophy Optic disc drusen Optic nerve coloboma Staphyloma Megalopapillae Tilted disc syndrome </p>	<p>Clover Leaf</p>  <p>Description: Diagonal paracentral points show normal or near-normal sensitivity but all other points reduced. This is often due to patient responding normally at the start of the test only as the visual field instrument generally test these points first. Often accompanied by high fixation loss and false negative. Differentials: <ul style="list-style-type: none"> Inattentive patient Poor supervision Malingering Retinal disease </p>



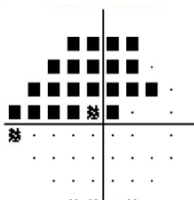
1. Vertical Step:

Generally respects the vertical midline with at least 2 points outside 15° of fixation.

2. Quadrant:

Visual field loss that respects both the vertical & horizontal midline. Suggestive of neurological involvement if bilateral. All points within the quadrant must be P<5%.

Note: Pituitary gland adenoma gives more superior defects (“pie-in-the-sky”) while parasellar lesions give more inferior losses (“pie-on-the-ground”).



3. Hemianopia:

Loss of the vertical hemifield respecting the vertical midline either partially or completely.

Note: Bitemporal hemianopia results from compromised nasal fibres of the optic nerves of both eyes due to injuries or lesions at the optic chiasm. Monocular temporal hemianopia may occur if the lesion is more anterior and only affecting the nasal crossing fibres from the ipsilateral eye.



::

4. Three Quadrants:

Three quadrants with all points at least P<5%. Partial three quadrant losses does not have all points P<5% but is greater than a complete hemianopia.

Differentials: As for vertical step. Multiple lesions or pathologies may also need to be considered.