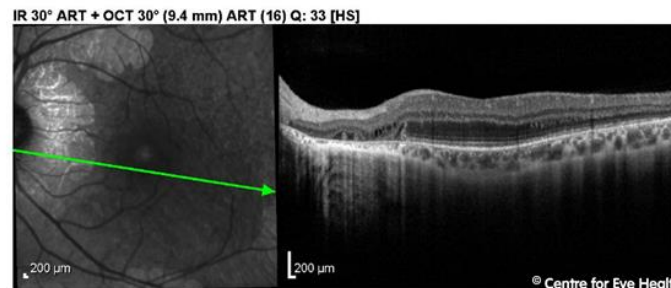
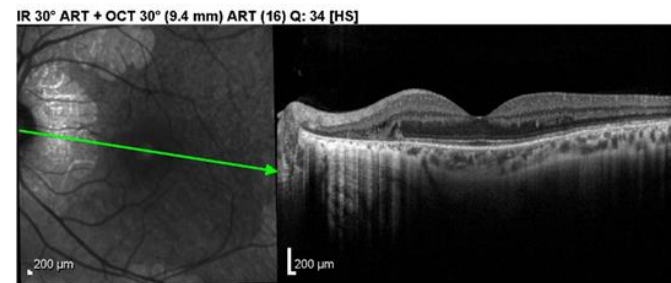
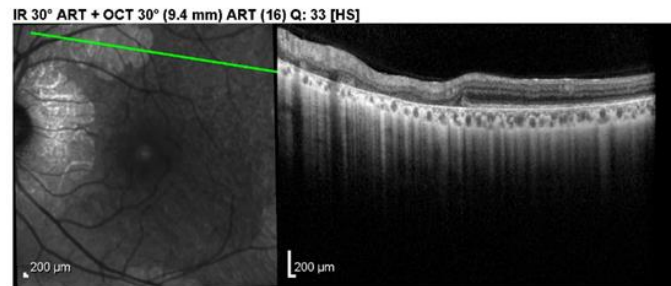
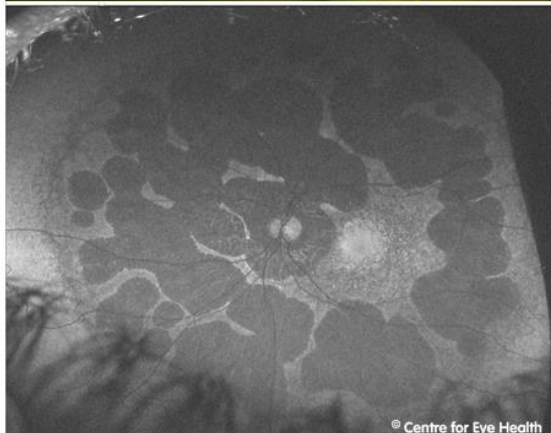
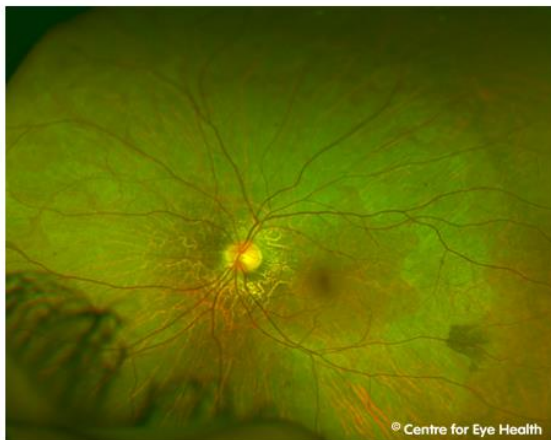



## CFEH Facebook Case #79

A 28 year old male presented for a peripheral retinal examination. He is asymptomatic and visual acuity is 6/6 in each eye. He is adopted and no family history is available. His imaging results are below (both eyes are similar so only the left is shown) and visual field testing showed a bilateral constriction of the fields. What retinal condition does this patient have?



Proudly brought to you by

**LEARNING FOR VISION**



Centre for Eye Health



Optometry

NEW SOUTH WALES

AUSTRALIAN CAPITAL TERRITORY

# ANSWER

This patient has gyrate atrophy.

Retinal imaging shows multiple areas of chorioretinal atrophy surrounding the posterior pole and midperipheral retina. There are well-defined areas of hypo-autofluorescence on fundus autofluorescence scans, with hyper-autofluorescence seen at the maculae.

Spectralis OCT line scans through areas of atrophy revealed thinning of the outer retinal layers and RPE. Imaging of the macula revealed macular thickening, outer retinal tubulation and mild cystoid macular oedema at the edge of atrophic areas near the fovea.

Gyrate atrophy is caused by a mutation to the ornithine aminotransferase (OAT) gene, resulting in a reduced amount of functional OAT enzyme. As a result, there is an accumulation of plasma ornithine which is toxic to the RPE and choroid. Early in the disease process, patients develop large peripheral areas of chorioretinal atrophy. These areas eventually coalesce forming a scalloped border peripherally, at the junction of normal and abnormal retina.

Nyctalopia (night blindness) usually occurs in the first decade of life, followed by a progressive loss of visual field and eventually central vision is also lost.

Treatment may involve dietary restriction of ornithine however success of this is limited. A small percentage of those with this condition do respond to vitamin B6 supplementation and this lowers the plasma ornithine levels however for most there is no effective treatment.