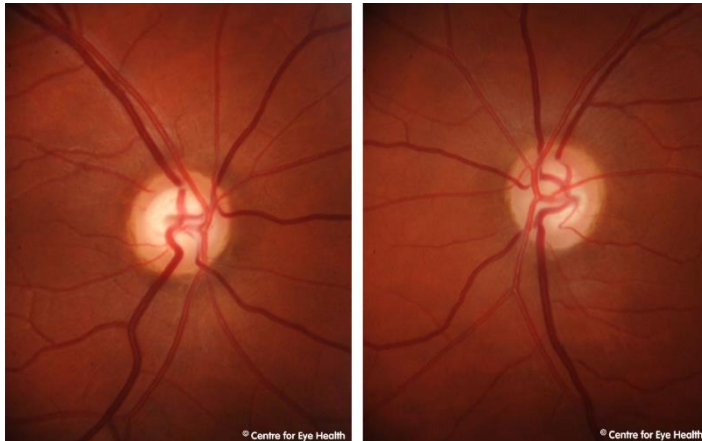


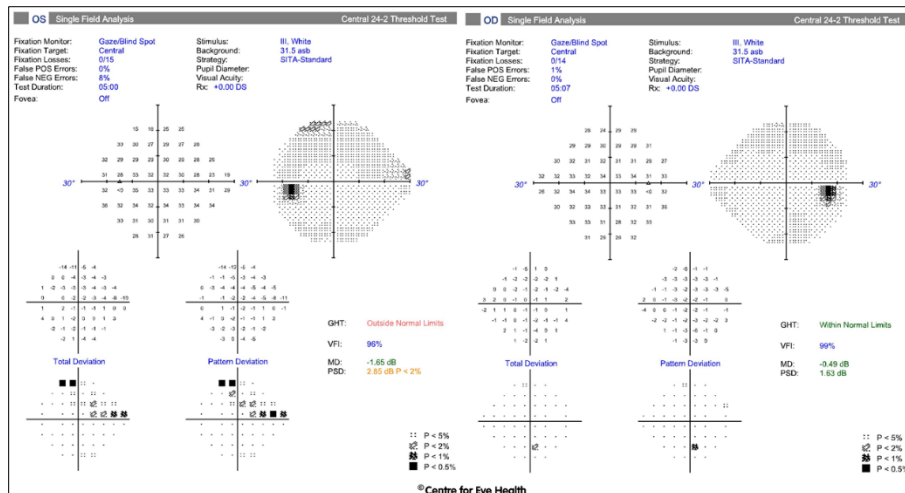
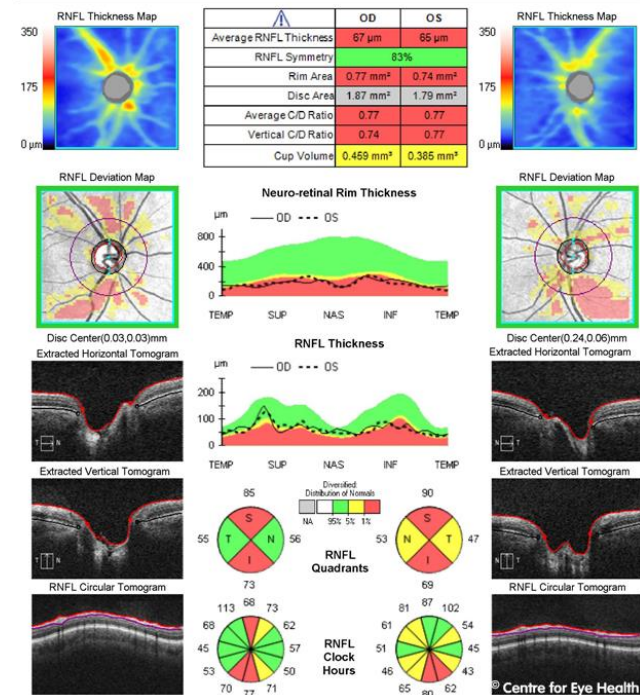


## CFEH Facebook Case #71

A 29 year old Caucasian female was referred for a glaucoma assessment. She suffers recurrent sinusitis and has used Nasonex (mometasone) daily for 5 years, but is otherwise healthy. There is no family history of glaucoma. Intraocular pressures were 31mmHg OD, 32mmHg OS and central corneal thickness 597µm OD and 603µm OS. Anterior examination was unremarkable and there were no signs of secondary glaucoma. Does this patient have glaucoma and if so, what type is most likely?



### ONH and RNFL OU Analysis: Optic Disc Cube 200x200 OD ● OS



Proudly brought to you by

**LEARNING FOR VISION**



Centre for Eye Health



Optometry

NEW SOUTH WALES  
AUSTRALIAN CAPITAL TERRITORY

# ANSWER

Our patient does have glaucoma, probably steroid-related due to prolonged use of nasal steroids.

IOP's are significantly elevated and corneas are thicker than average. Discs are average sized and show large cupping with thin superior and inferior rims. Visual fields show a superior arcuate defect in the left eye. Cirrus RNFL analysis shows thinning of the RNFL in both eyes in a pattern consistent with glaucomatous loss.

Nasonex (mometasone) is a steroid based nasal spray used to treat allergies. Recent studies have not shown an association between glaucoma and mometasone. However given there is no family history of glaucoma it is likely that this patient is a steroid responder and the effects of nasal steroids has not been studied on this group.