

CFEH Facebook Case #16

A 68 year old Caucasian female was referred for glaucoma assessment. She reported no relevant ocular symptoms, although she mentioned that her intraocular pressures have always been noted to be high. Otherwise, she has no other contributory ocular or family history. She takes medications to treat depression, and is on hormone replacement therapy.

Aided VAs were 6/7.5-1 OD and OS, with a moderate hyperopic and astigmatic script.

Corneal thicknesses were 562 microns OD and 560 microns OS.

Intraocular pressures with applanation tonometry were 27 mmHg OD and 24 mmHg OS.

Gonioscopy showed wide open angles OU. The anterior segment was unremarkable, with no evidence of risk factors for secondary glaucomas.

Photos of the optic nerve, red-free posterior pole photographs and Cirrus OCT RNFL images are below.

What would you expect to find from the visual field result?

Proudly brought to you by
LEARNING FOR VISION

Proudly brought to you by

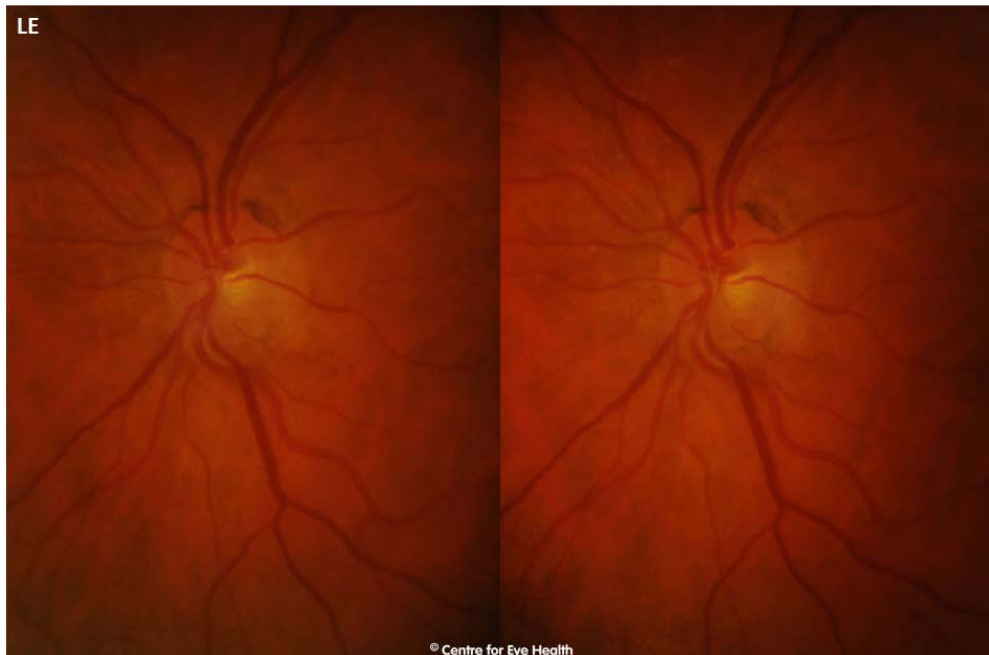
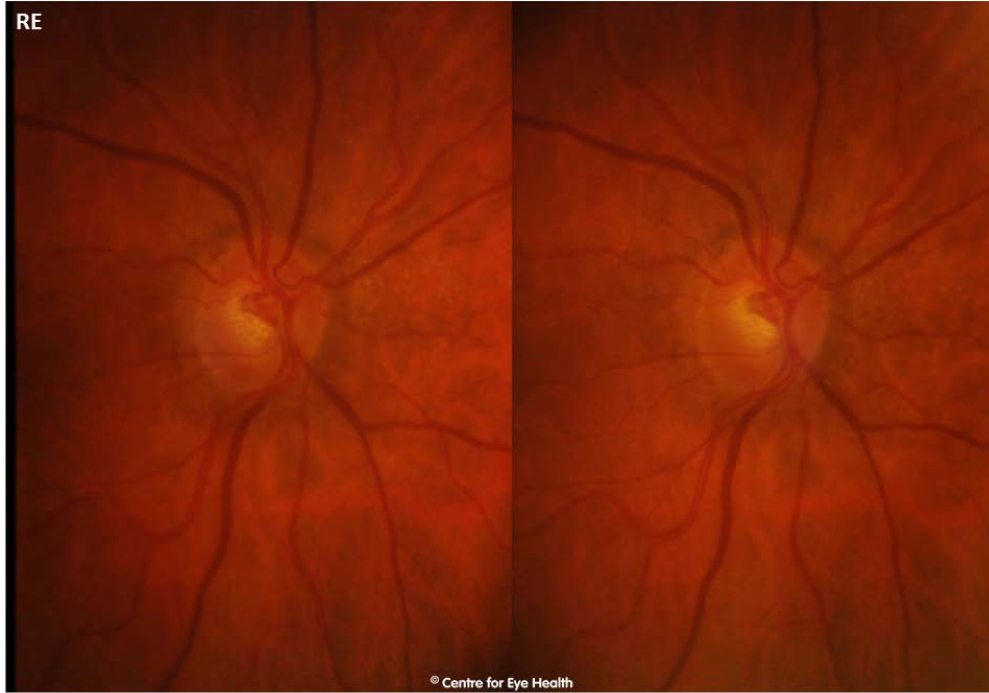
LEARNING & VISION

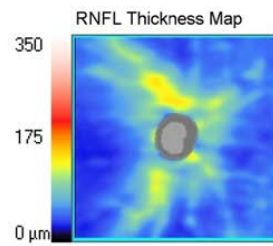
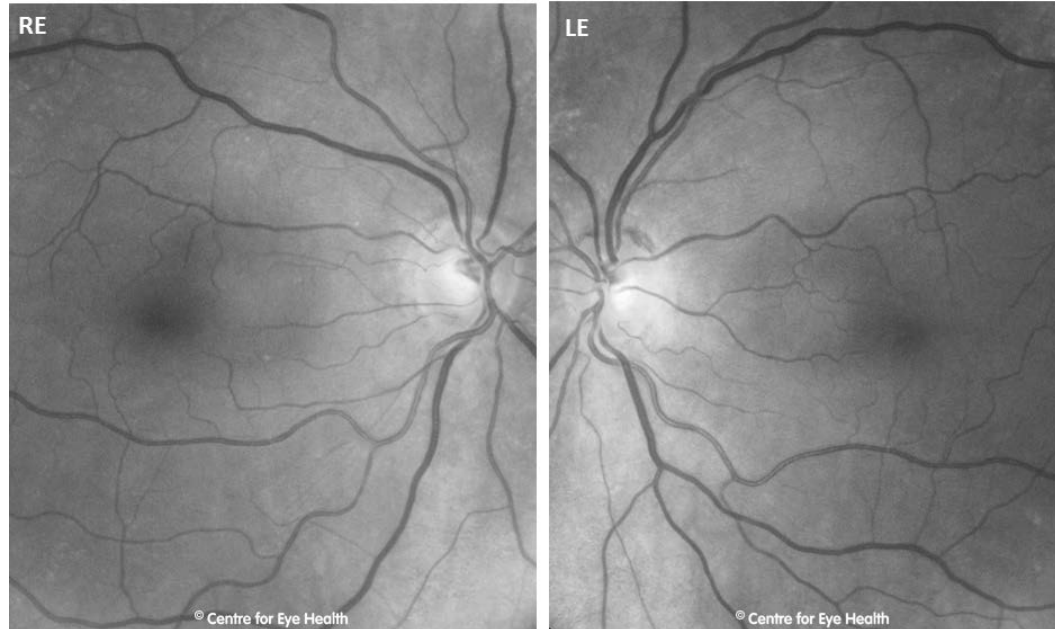


Centre for Eye Health

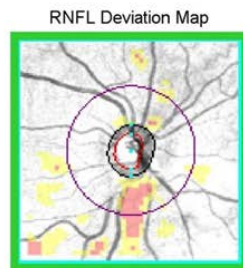
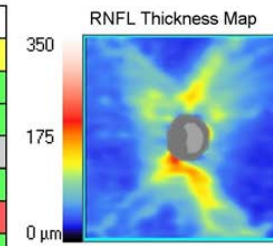


Optometry
NEW SOUTH WALES
AUSTRALIAN CAPITAL TERRITORY

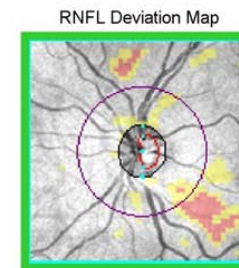
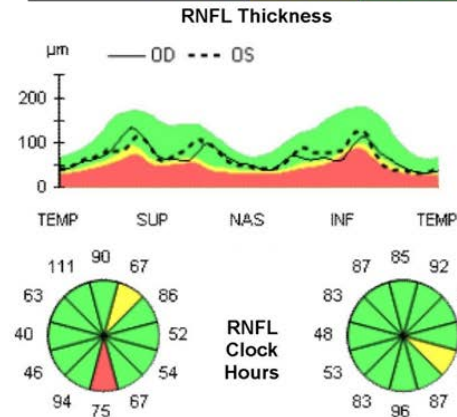




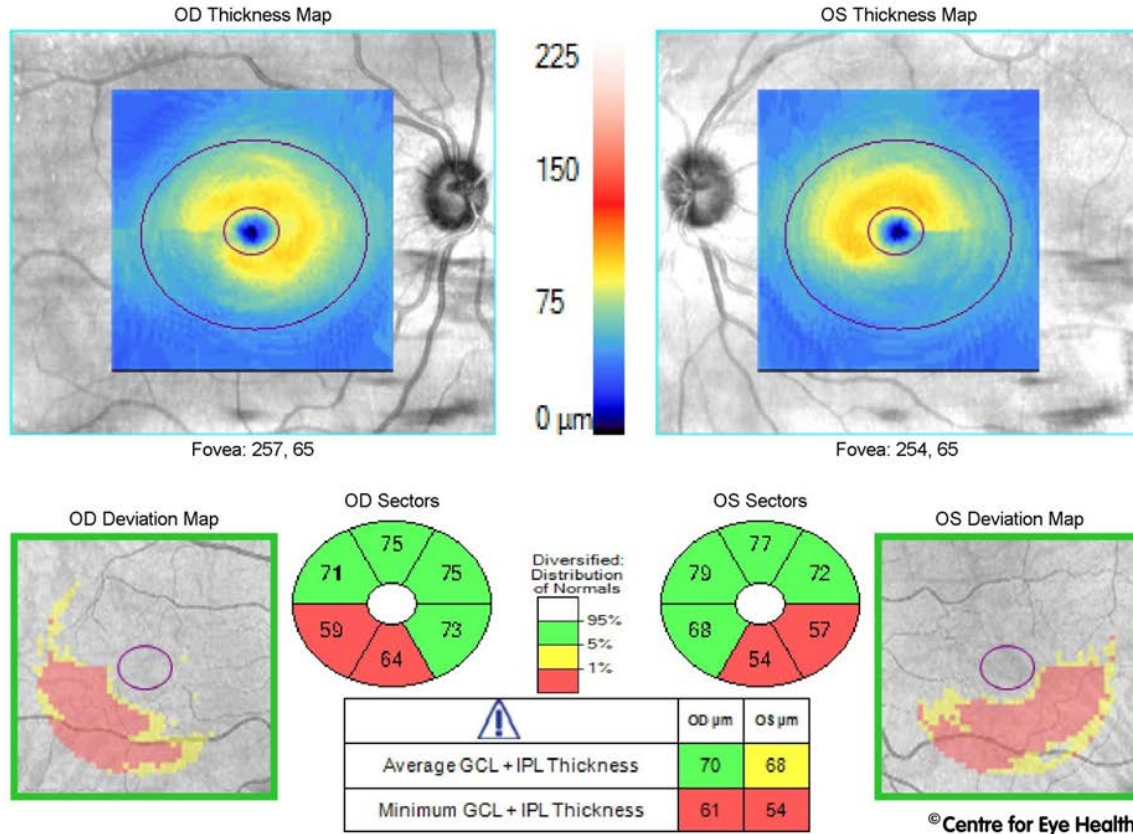
	OD	OS
Average RNFL Thickness	70 µm	72 µm
RNFL Symmetry	84%	
Rim Area	0.80 mm ²	1.01 mm ²
Disc Area	1.38 mm ²	1.39 mm ²
Average C/D Ratio	0.64	0.52
Vertical C/D Ratio	0.70	0.67
Cup Volume	0.217 mm ³	0.121 mm ³



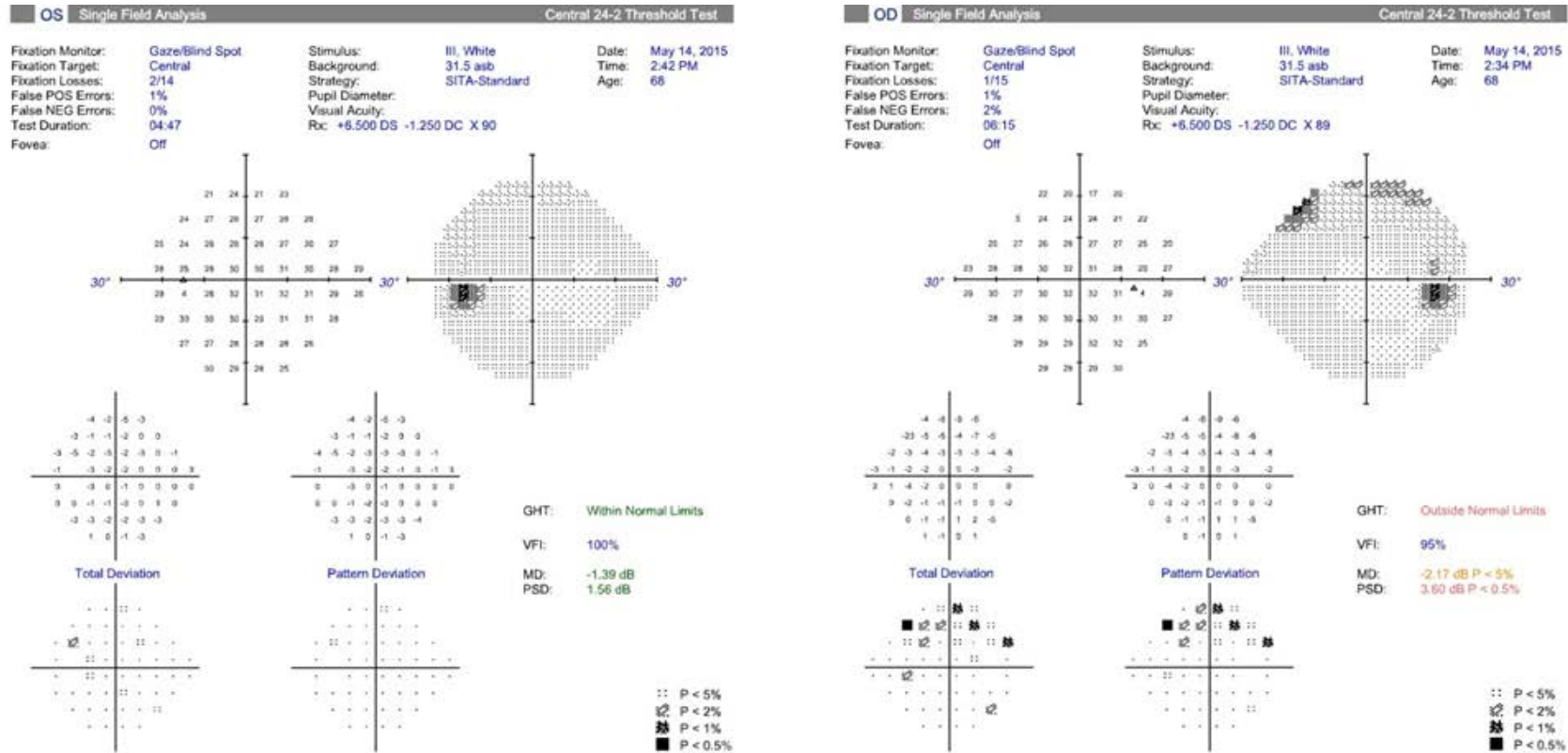
Disc Center(0.00,0.06)mm



Disc Center(0.03,0.03)mm



ANSWER



© Centre for Eye Health

Although we find, as expected, a superior arcuate-type defect in the right eye which exhibits structure-function correlation with the inferior NRR (seen in stereo), RNFL and GCIPL loss, the left eye result is surprisingly clear. This is in spite of structural findings that are not too dissimilar between the eyes (for example, the RNFL symmetry index was at 84%; comparison of raw GCIPL thickness values between the eyes in fact shows the left eye to be slightly more depressed).

Poor structure-function relationship has been noted in a high number of cases of early glaucoma, whereby some patients show obvious signs of structural loss with absent visual field defects (i.e. pre-perimetric glaucoma). The visual field results of such patients have been found to be different to that of a completely healthy patient, however the results are all generally "green", and show no failure of any typical visual field criteria for defect (e.g. MD, PSD, event analysis).