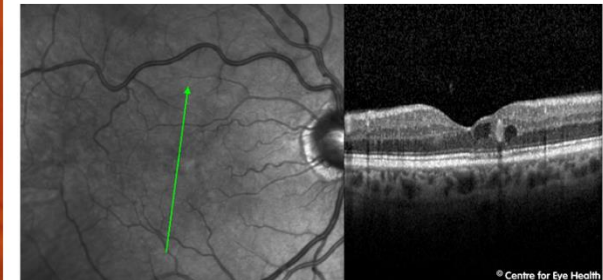
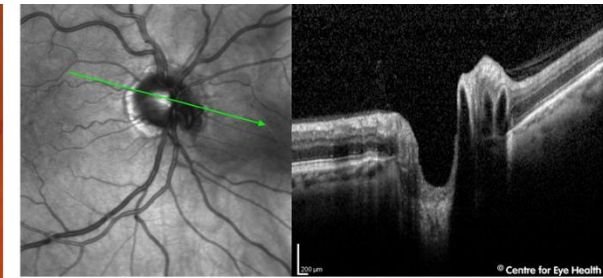
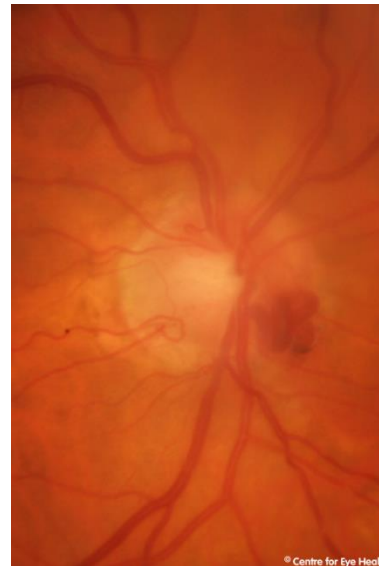
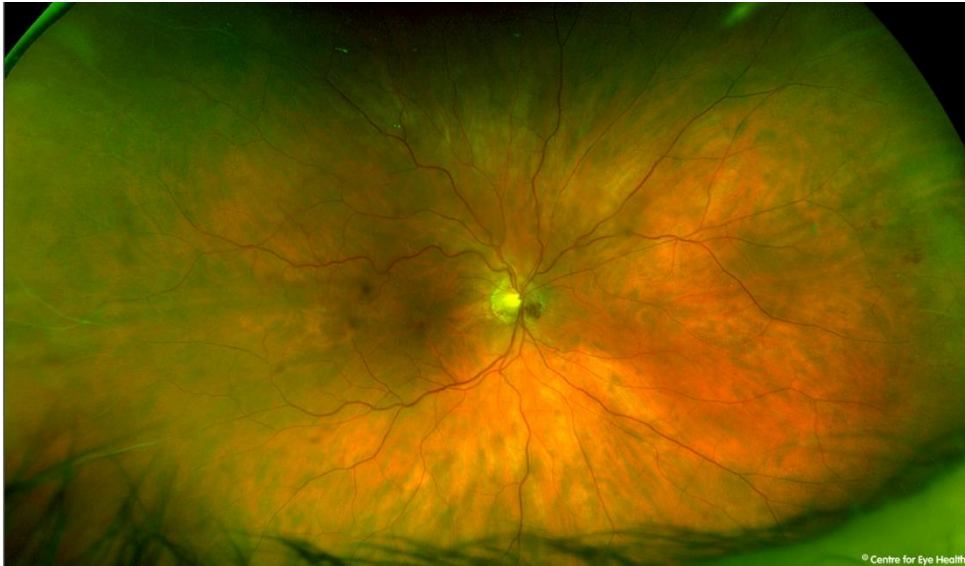



## CFEH Facebook Case #54

A 64 year old Caucasian male was referred for an optic nerve assessment. He has long-standing floaters but is otherwise asymptomatic and takes several medications for cardiovascular disease and blocked carotid arteries. To his knowledge he is not diabetic and has no other relevant family or ocular history. Unaided acuities were 6/12- OD (OHNI) and 6/6- OS. What retinal condition(s) does this patient have?



Proudly brought to you by

LEARNING FOR VISION



Centre for Eye Health

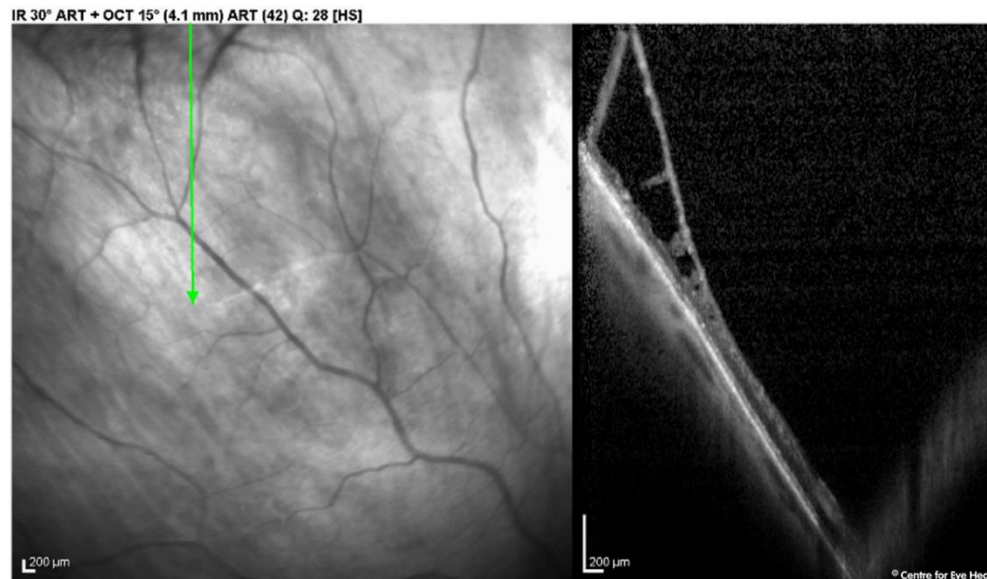

Optometry  
NEW SOUTH WALES  
AUSTRALIAN CAPITAL TERRITORY

# ANSWER

There is an anomalous blood vessel which appears to loop and corkscrew around on the nasal aspect of the right disc, suggestive of a shunt vessel. Spectralis OCT through the optic nerve shows a focal hyper-reflective lesion which appeared co-localised with the vascular anomaly seen on the retinal images. An OCT through the right macula showed a number of cystic spaces, consistent with cystoid macular oedema, and accounting for the reduced vision. It also shows a hyper-reflective lesion adjacent to the cystic space at the macula. This is another anomalous blood vessel, visible during the examination but not clear on the Optomap image.

Optomap imaging shows numerous microaneurysms and dot/blot haemorrhages almost 360 degrees in the peripheral retina, a finding present in both eyes. Incidentally, peripheral examination also showed a raised area superiorly to superotemporally in the right eye. Spectralis OCT through this region (below) confirmed the presence of a retinoschisis.



This patient was referred to a retinal specialist ophthalmologist for an opinion and a review of the patient's vascular risk factors with his GP was also recommended. The anomalous shunt vessel is hypothesized to have developed secondary to a retinal vein occlusion.