


# image



Centre for Eye Health

NEWSLETTER FOR OPTOMETRISTS

With the increasing prevalence of systemic vascular disease there will also be a corresponding increase in the amount of retinal vascular disease that will be seen by optometrists in practice.



clinic update

Understanding the systemic and ocular relationship is complex but essential. It requires an understanding of the human body that is much more expansive than most other eye-related diseases.

It is for these reasons the Centre has invited a range of medical professionals - including a cardiologist, scientist, ocular oncologist and retinal specialists - to present at this year's full-day SCOPE event "Blood Vessel Diseases: I to Eye".

This outstanding line-up of speakers will share their diverse experience and expertise to ensure participants receive an all-encompassing knowledge of blood vessel disease and instill confidence when seeing at-risk or suspected patients in practice.

It is a day I hope many of you attend and a matter we all work hard to overcome.

I would also like to take this opportunity to remind those of you purchasing your own imaging equipment that our virtual consult service is now available as part of the Learning for Vision membership.

If you capture an image from your equipment, and you're just not sure what that image is telling you, please don't take a guess. Get a second opinion from our team of expert optometrists and ophthalmologists and be confident in your diagnosis - it could save your patients eye sight.

Once again, I would like to thank those of you who have supported the Centre by joining Learning for Vision and those who refer regularly. Your support ensures our great service continues.

**Prof. Michael Kalloniatis**  
Centre Director

- Our full-day SCOPE session "Blood Vessel Diseases: I to Eye" is taking place on Sunday 27<sup>th</sup> October. For more information on the day or to register visit [www.cfeh.com.au](http://www.cfeh.com.au)
- Our Learning for Vision online CPD program has now issued over 250 points worth of online learning activities and is growing weekly. To become a member or learn more visit [learningforvision.com.au](http://learningforvision.com.au)
- For those who have their own imaging equipment, please remember our virtual consult service is now up and running and available on the Learning for Vision site.
- A reminder that the Centre now distributes all patient reports electronically via Medinexus. If you have not yet set-up your Medinexus account please e-mail [enquiries@cfch.com.au](mailto:enquiries@cfch.com.au) for an instruction sheet.
- Please remind your patients to take their Medicare card with them to their CFEH appointment, as where appropriate we bill for optometrist to optometrist referrals (10905).

**"We are very appreciative of the wonderful care your staff gave us"**

Eddie & Irene, CFEH patients 2013

## case profile:

Matt, a 36 year old Caucasian male, presented for a routine eye examination to his optometrist.

The optometrist found a recent change in Matt's prescription and suspected a pathological cause. As a result, Matt was referred to the Centre for Eye Health (CFEH) for further investigation.

Entering aided acuities were RE +1.50/-1.75x 75 6/6 LE +1.00/-1.00x90 6/6

His ocular history and family ocular history were unremarkable. His general health was also unremarkable apart from mild hay fever.

Issues to consider:

- What pathological ocular conditions can give rise to refractive error changes?
- What instruments can determine the integrity of the eye's optical elements?
- What are some differential diagnoses for alterations in the eye's corneal refractive power?

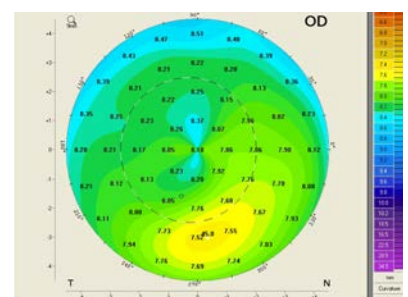


FIGURE 1: Sagittal corneal topography map from Matt's Right eye

continued overleaf

case profile cont...

**Results and Discussion**

Changes in refractive error can have optical or anatomical origins. Optical origins encompass changes in corneal or lenticular refractive power through changes in refractive surface curvature (cornea or lens) or media refractive index (cornea, lens or vitreous).

Anatomical origins include changes in axial length or changes in separation between the eye's optical elements.

Potential pathological causes include Keratoconus, Keratoglobus, Pellucid Marginal Degeneration, Anterior segment trauma, Pterygium, Metabolic Changes (for example, diabetes) and Cataract.

**Assessment at CFEH**

Tests performed at CFEH included Anterior OCT (Optovue), Pentacam and Medmont E300 corneal topography, and Irx3 Wavefront aberrometry.

Slit lamp examination and Optovue OCT showed a clear cornea with no corneal folds or scarring in either eye. Pentacam and E300 topography showed mild thinning and steepening of the inferior peripheral cornea in both eyes with 'crab-claw' appearance (Figures 1 and 2).

Tangential maps on Pentacam revealed the area of steepening to be 1-2mm above the limbus in each eye. (Figure 3A and 3B).

Corneal thicknesses at the pupil centre were RE 550 µm and LE 552 µm with the thinnest locations measuring RE 528 µm and LE 526 µm.

The Irx3 wavefront aberrometer showed increased higher order aberrations in both eyes. The root mean square (RMS) wavefront error, representing the average total amount of higher order aberrations, for a healthy eye with pupil diameter of 5mm will typically measure between 0.20 and 0.30 µm. Matt's RMS wavefront error was 1.7 µm in the right eye and 1.21 µm in the left eye.

The findings, notably the crab-claw topography, are consistent with pellucid marginal corneal degeneration. Slit lamp examination can differentiate pellucid marginal degeneration from

keratoglobus, anterior segment trauma, diabetes and cataract.

Corneal topography can usually differentiate keratoconus from pellucid marginal degeneration, as keratoconus typically shows an asymmetrical bow tie with inferior steepening of the cornea and thinning of the cornea whilst pellucid marginal degeneration shows a "crab claw" pattern. Matt was recommended to return for repeat imaging in 6 months to check for progression. If significant progression is found in either eye, referral to a corneal specialist would be considered to assess suitability for different treatment options.

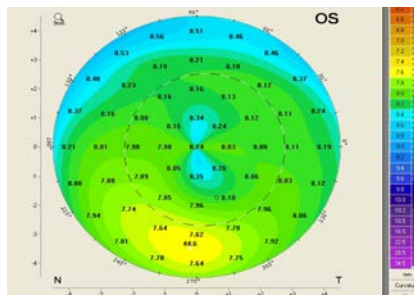


FIGURE 2: Sagittal corneal topography map from Matt's Left eye

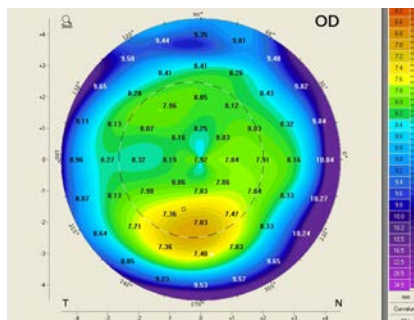


FIGURE 3A: Tangential corneal topography map from Matt's Right eye

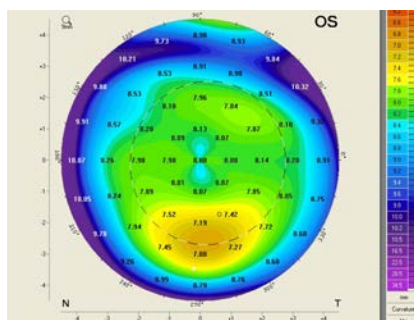


FIGURE 3B: Tangential corneal topography map from Matt's Left eye

**spotlight on Pellucid Marginal Degeneration**

“Pellucid”, a word derived from Latin and by definition meaning “through clear” (transparent), was first used by Schlaeppli<sup>1</sup> to describe clarity of the cornea in the presence of ectasia.

Pellucid marginal degeneration (PMD) is usually a bilateral condition characterised by thinning of the peripheral cornea (Figures 4 and 5), usually in the inferior cornea and distinguished by a band of thinned cornea 1-2mm in width, within the 4 to 8 o'clock position<sup>2-4</sup>. The region of thinning classically sits above the limbus separated by an area of normal, unaffected cornea<sup>3,5</sup>.

Atypical cases, in which there is unilateral PMD<sup>6-8</sup> and superior<sup>9-11</sup>, temporal<sup>10</sup> and nasal<sup>10</sup> rather than inferior thinning of the cornea have been reported in the literature. The thinning within the affected band of cornea can reach up to 80% of stromal

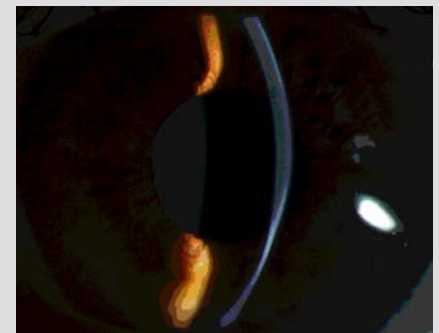


FIGURE 4: Slit-lamp optical section highlighting peripheral corneal thinning in PMD.

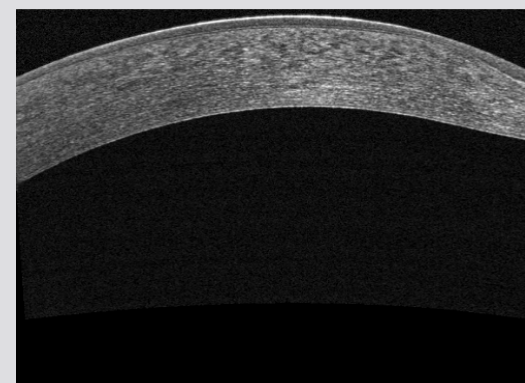


FIGURE 5: Optovue anterior OCT through the cornea of the same eye as Figure 3.

tissue lost in advanced cases<sup>3</sup>. To date, there are few studies reporting the incidence of perforation in PMD, however, a review by Grewal et al of patients with keratoconus and PMD seen in a 2.5 year period included 22 eyes with hydrops, of which 19 patients had keratoconus and two had PMD<sup>12</sup>.

Corneal topography with placido disc method (e.g., Medmont E300) or Scheimpflug tomography (e.g., Pentacam HR) is commonly utilised to detect and diagnose PMD. The classical corneal contour has been described in the literature as a “crab claw”<sup>9</sup> which shows the shift in astigmatism from superior to inferior cornea. The “claw shape” pattern (Figure 6) is the diagnostic key to PMD, however it may be present in other ectatic conditions such as keratoconus, thus slit-lamp findings, such as the presence of inferior peripheral corneal thinning, should be evaluated alongside corneal topography for a more definite diagnosis<sup>13</sup>.

Tangential maps are most useful in highlighting the band of thinning when analysing the corneal topography, with the band of thinning seen 1-2mm above the limbus.

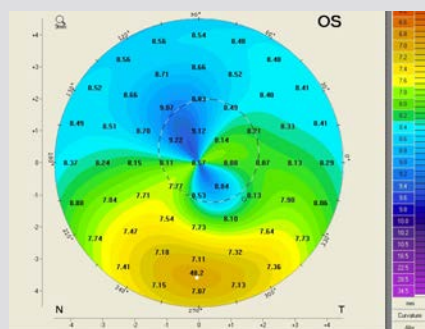
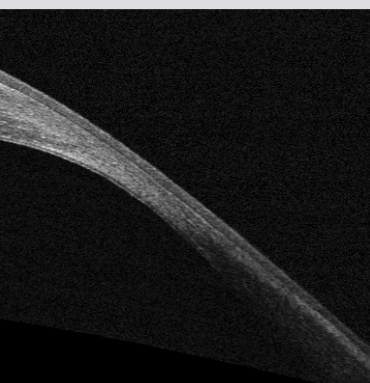


FIGURE 6: Medmont E300 Axial Map showing classic “Crab claw” topography



### Distinction from Keratoconus and Other Corneal Thinning Disorders

Many cases of PMD are often misdiagnosed as keratoconus in the early stages of the condition. In PMD, the best corrected visual acuity is only significantly affected in later stages, whilst in keratoconus the visual acuity may be reduced in early stages. Patients with PMD usually report a gradual reduction in vision<sup>1</sup>. The hallmark “scissors” or “oil drop” reflex seen in keratoconus is also unlikely to be seen in PMD until advanced stages of the disease<sup>1</sup>.

In addition to the aforementioned corneal topographical features of PMD, slit-lamp signs such as Fleischer’s ring, apical corneal scarring, Vogt’s striae and Munson’s sign are not seen in PMD and are only characteristic of keratoconus<sup>1</sup>. The pachymetry measurements in PMD are also likely to indicate normal central corneal thickness as opposed to the thinning seen in keratoconus<sup>1</sup>.

Other differential diagnoses of PMD include keratoglobus, Terrien’s marginal degeneration and Mooren’s ulcer. Keratoglobus is less common than PMD and is a bilateral ectatic disorder where the cornea develops a rounded appearance due to overall thinning, with keratometry reaching 60-70D<sup>14</sup>. Fleischer’s ring, Vogt’s striae, and scarring are uncommon in keratoglobus. In keratoglobus however, breaks in Descemet’s membrane can cause opacity and oedema within the cornea<sup>15</sup>.

Terrien’s marginal degeneration is a slowly progressing bilateral marginal corneal ectasia which usually begins in the superior cornea and develops into circumferential thinning<sup>3</sup>. The patients are typically male and in their mid-twenties<sup>16</sup>. Slit-lamp findings which may be visible in early Terrien’s marginal degeneration include peripheral neovascularisation with marginal opacification. Peripheral corneal thinning occurs in the area between the limbus and the area of opacification and leads to lipid deposition as the thinning develops<sup>3</sup>. Terrien’s marginal degeneration shows flattening of the cornea within the areas of peripheral thinning. As Terrien’s is a non-inflammatory condition complaints of acute pain are uncommon, however

patients usually report ocular irritation<sup>16</sup>.

Mooren’s ulcer is a painful, inflammatory ectasia of the peripheral cornea which may be unilateral or bilateral<sup>3</sup>. Mooren’s ulcer typically begins at the inferior limbus, with the presence of perilimbal corneal infiltrates and epithelial defects and the development of an ulcer that may spread around the limbus and then proceeds centrally, eventually affecting the whole cornea. As the ulcer heals, vascularisation occurs<sup>17</sup>.

The literature suggests that PMD can be differentiated from Terrien’s marginal degeneration and Mooren’s Ulcer as the thinned cornea in PMD is clear, avascular, without lipid deposition and exhibits an intact epithelium<sup>1,3</sup>.

### Epidemiology

Currently, the precise aetiology of PMD is unknown and it is not conclusive as to whether keratoconus and keratoglobus are variations of the same disorder or if it is a distinct disease on its own<sup>2,3,18</sup>. Several authors have proposed that PMD is a form of keratoconus<sup>1,5</sup> and other studies have recorded the occurrence of PMD alongside keratoconus and associated with keratoglobus<sup>4</sup>.

The incidence and prevalence of PMD has not been assessed, however the literature suggests PMD is relatively less common than ectatic diseases such as keratoconus<sup>2,3,18</sup> but more common than posterior keratoconus and keratoglobus. Additionally, the number of PMD cases may not be a true reflection of the prevalence due to some misdiagnoses of keratoconus as PMD.

Recent studies have suggested greater incidence of PMD in males<sup>19, 4, 20</sup>. Prior to these studies there was no gender predilection reported<sup>2,3,18</sup>.

At present the literature proposes no geographic disposition and affects all ethnicities<sup>1-3,18</sup>.

There is no evidence PMD is an inherited disease although the literature reports corneal topography suggestive of corneal ectasia and incidences of moderate to high astigmatism in asymptomatic family members of a PMD patients<sup>1,15,21</sup>.

## our contact details

The University of New South Wales,  
Rupert Myers Building (south wing), Kensington NSW 2052

Ph: (02) 8115 0700/1300 421 960  
Email: [enquiries@cfeh.com.au](mailto:enquiries@cfeh.com.au)

Fax: (02) 8115 0799  
Website: [cfeh.com.au](http://cfeh.com.au)



Centre for Eye Health is an initiative of  
Guide Dogs NSW/ACT and The University of New South Wales

## Pellucid Marginal Degeneration cont....

### Natural Prognosis and Treatment of PMD

PMD is a slowly progressing disorder typically diagnosed between the second and fifth decades of life<sup>18</sup>. It typically begins with a mixed hyperopic astigmatic prescription.

In early stages PMD is managed with nonsurgical methods such as spectacles and soft toric contact lenses as the astigmatism is typically regular within the pupil area at this point.

RGP contact lenses are used in moderate to advanced PMD cases due to the onset of irregular astigmatism. Use of standard diameter RGP lenses however will show inferior edge lift due to the inferior corneal steepening.

A number of papers have been published<sup>19,20,22,23</sup> suggesting a larger diameter be fitted to achieve adequate lens stability and good visual acuity. Bi-toric RGP contact lenses will also typically be required.

When there is evidence of progression, surgical methods such as collagen cross-linking, and intracorneal ring segments (e.g., Intacs, KeraRings) are considered. In advanced PMD, penetrating or lamellar grafts are the treatment modality.

### Collagen cross-linking

The advent of Collagen Cross-linking in recent years has led to treatment of the disease before it progresses to moderate or advanced stages.

Kymionis et al<sup>24</sup> reported a case where a patient underwent simultaneous PRK and cross-linking procedures which led to an improvement in visual acuity. Although collagen crosslinking has been used primarily in the treatment of keratoconus, further studies are needed to evaluate the efficacy in pellucid marginal degeneration.

### Penetrating keratoplasty

In cases where visual acuity is reduced and cannot be improved with spectacles or contact lenses, penetrating keratoplasty (PK) can be considered. It is, however, not ideal, given the peripheral nature of the disease. The corneal thinning found adjacent to the limbus in PMD requires the introduction of large diameter corneal grafts; unfortunately the proximity of the graft to the limbus gives rise to issues such as increased risk of graft rejection, neovascularisation and suture-induced complications<sup>1,25</sup>.

### Intracorneal ring segments

Intrastromal corneal ring segments (e.g. Intacs, Kerarings) have been used in attempts to treat the high corneal astigmatism found in keratoconus and more recently, pellucid marginal degeneration.

There are few papers describing the long-term effects of intracorneal ring segments in the treatment of pellucid marginal degeneration. In the short-term (post-operative results out to 12 months) intracorneal ring segments have been shown to improve uncorrected VA<sup>26-29</sup>, improve BCVA<sup>27,29</sup> and reduce refractive error in PMD. Other studies however have shown no statistically significant changes in some of the above parameters (including uncorrected VA and BCVA) at 6 months after intracorneal ring implantation<sup>30</sup>. In recent years interest in intracorneal ring segments as a standard treatment modality for PMD has declined.

*This edition of Image Newsletter has been prepared by Elizabeth Wong, Staff Optometrist and has been adapted from the CFEH's 'Image Extra' series on the LearningforVision website ([www.learningforvision.com.au](http://www.learningforvision.com.au)).*

*To access previous editions of Image Newsletter, or to download additional resources and references, please visit [www.cfeh.com.au](http://www.cfeh.com.au).*

## Support the Centre

The Centre for Eye Health needs your support to continue providing this great service.

By becoming a Learning for Vision member you can directly support the Centre and the services it provides.

In return you will be provided the opportunity to complete over 40 CPD points in advanced imaging education and given exclusive access to our virtual consults service.

For more information on the Learning for Vision program visit [www.learningforvision.com.au](http://www.learningforvision.com.au).

*Thank you to our valued referrers for your continued support.*

**“This is a great initiative & deserves widespread recognition and support”**

Ken, CFEH patient 2013

## did you know?

**A Referrer Hotline is available for registered optometrists.**

**REFERRER HOTLINE: 8115 0777**

Disclaimer: This newsletter is not intended to provide or substitute advice through the appropriate health service providers. Although every care is taken by CFEH to ensure that this newsletter is free from any error or inaccuracy, CFEH does not make any representation or warranty regarding the currency, accuracy or completeness of this newsletter. Patient names and details have been changed to protect privacy. Copyright: © 2012, Centre for Eye Health Limited. All images and content in this newsletter are the property of Centre for Eye Health Limited and cannot be reproduced without prior written permission of the Director, Centre for Eye Health Limited.